II—On the Development of the Blood Vessels in the Head of the Chick

By A. F. W. Hughes

Sub-department of Vertebrate Zoology in the University of Cambridge

(Communicated by C. Shearer, F.R.S. Received November 27, 1933—Read May 31, 1934)

[Plates 1–16]

Contents

Page
I. Introduction 75
Methods 76
General review of previous work 78
II—The Arteries
Review of Miss Sabin's paper 79
The aortic arches and internal carotid 81
The external carotid 89
The stapedial artery 94
The vertebral and subclavian arteries, and the backward migration of the aortic arches 98
III—The Veins
Account of previous work on the development of the head veins 106
The ventro-lateral longitudinal veins 109
The mid-dorsal longitudinal vein 117
IV. Discussion 118
V. Summary 125
VI. References 126
VII. Key to Lettering 127

I—Introduction

The interest of the writer was first directed towards the study of the blood vessels of the head by comparing a dissection of the head arteries of the pig with one of the corresponding vessels in the pigeon. Both systems of vessels include a rete mirabile, but whereas that of the pig interrupts the internal carotid just before its entrance into the sella turcica, that of the pigeon corresponds to the temporal rete of the chick described in the present communication, and is found in the orbit in no immediate connection with the internal carotid. It was difficult to see how a

VOL. CCXXIV.—B 510 (Price 18*s*.) L [Published December 3, 1934

The Royal Society is collaborating with JSTOR to digitize, preserve, and extend access to *Philosophical Transactions of the Royal Society of London. Series B, Biological Sciences.* www.jstor.org

common functional explanation could be applied to both these retia. My attention was then drawn to the work of SHELLSHEAR, who from comparative studies of the distribution of the encephalic arteries in adult material had advanced certain hypotheses, summarized later in this communication, regarding the way in which blood vessels were supposed to develop. The most direct way of testing SHELLSHEAR's hypotheses seemed to be that of studying intensively the development of the blood vessels in a single form.

The examination of the literature of the development of the vascular system revealed the fact that hardly ever, if at all, had the development of arteries and veins been studied at the same time. Moreover, through the development of technique for the injection of embryonic material, it had been shown in many forms that a preliminary stage of capillary plexus is antecedent to definitive blood vessels. Yet although comparatively early embryos of birds and mammals had been studied by this means, no work had been done on any form in following the development of the blood vessels from the earliest stages to the adult condition. For the chick, Miss SABIN had given an account of the development of the blood vessels from·the earliest stages up to the twenty-nine somite stage, SABIN (1917). It was decided to attempt to continue this account of the development of the blood vessels of the chick for the remainder of the embryonic period.

I am grateful to Professor J. STANLEY GARDINER, F.R.S., and to Mr. C. FORSTER-COOPER for the privilege of working in the Zoological Department and the Museum of Zoology respectively of the University of Cambridge. I am further indebted to Mr. C. FORSTER-COOPER for much help and to Dr. S. M. MANTON for her never failing advice and assistance in many matters of histological technique, and in the preparation of illustrations. Mr. G. R. DE BEER was good enough to offer advice on certain matters, as was Mr. W. J. HEASMAN on the subject of the preparation of transparencies.

Methods

A review of the injection technique used by the American school of workers has been given by SABIN (1915). I at first followed KNOWER's method (KNOWER, 1908) of injecting by means of small glass bulbs whose stems were drawn out into fine cannulæ. The bulbs are heated to expel air, and on cooling draw in the ink used as an injection mass, which can be expelled during the process of injecting by warming once more. This method, however, I at once abandoned on trying the earlier method of POPOFF (1894). This consists in blowing in the ink from a tube drawn out into a cannula by means of a piece of rubber tube attached at one end to a mouthpiece. This was found to be much more sensitive and satisfactory in every way.

The injections were made under a Leitz binocular magnifier arranged to give a magnification of 30 ×. Attached to the stand of the magnifier were two ball-and-socket arms ; one carried a small lamp for indirect lighting, supplied by Leitz, and the other the injection cannula. Eggs were opened, and held steady in a dish the floor of which was covered with plasticene, while the vitelline circulation was observed through the binocular magnifier. Injection was carried out while the egg was still in the shell, and without the addition of warm saline. Any vitelline vessel carrying a rapid stream of blood towards the heart was selected, and into it was introduced, in the direction of the blood stream, the cannula charged with freshly filtered Indian ink.

It was necessary to take a minute quantity of distilled water into the end of the cannula to prevent soiling the surface of the embryo with ink which would otherwise escape before the cannula could be introduced.

Pressure was applied with the mouth until the injection was complete. The embryos were then fixed either in neutral formalin, or alcoholic Bouin, and left in fixative for a period depending on the age of the embryo. The formalin fixed material was washed in tap-water, dehydrated, and cleared in benzine. It was next transferred to oil of wintergreen, when the tissues became perfectly transparent, and all that could be observed was the vascular system, black with the contained ink.

For most of the period in development for which this method was applicable, oil of wintergreen was found a satisfactory clearing agent. In embryos of five days incubation and over, however, the addition of a medium of higher refractive index, such as benzoyl benzoate, facilitates the study of deeper layers of the embryo than would be possible with the use of pure wintergreen oil alone. Such an embryo needs to be studied in media of different refractive indices.

Embryos fixed in Bouin were dehydrated and cleared in the same manner, and afterwards embedded in paraffin of 66 m.p., with a preliminary bath of half oil of wintergreen and half paraffin. As much as possible was made out of the vascular system before embedding, and this was compared with the picture obtained from the study of serial sections. Various alternative methods were employed in correlating the observation of whole mounts with the study of serial sections. Thus in the four and a half day embryo of fig. 7, Plate 4, the left half was cut into sections and the right half mounted whole. The figure is a drawing of the right half, with certain features lying to the left of the plane of section reconstructed afterwards. Another method was to cut alternately very thick sections at about 50μ, with a few consecutive sections at 10μ. Both these methods were attempts to surmount the difficulty experienced in seeing very much of the general vascular system in whole mounts beyond the four and a half day stage, due to the profusion of the capillary plexus in certain regions.

No attempt was made towards the end of development to study whole mounts. Such capillary systems of later stages which could be proved antecedent to definitive vessels it was found possible to study satisfactorily in transverse sections of injected material.

Sections were cut in paraffin throughout. In stages beyond that of twelve days, the practice was adopted of embedding in the ordinary way, and of cutting sections until a fault in the interior of the block was disclosed, due to contraction of the wax on cooling. Such faults were invariably encountered in large blocks. Re-embedding was resorted to, and the process of section cutting continued. In this way it was found possible to prepare a satisfactory series of sections of the head of a chick at the hatching stage with one re-embedding. Material of such later stages was first of all decalcified in 5% nitric acid in 70% alcohol for twenty-four hours and the horny beak dissected off. Staining in bulk was resorted to for the later stages, material at stages earlier than that of twelve days being stained as sections on the slide. Delafield's hæmatoxylin and eosin were employed as stain and counterstain respectively throughout. To obtain a good counterstain, it was found necessary to avoid overstaining with the hæmatoxylin, and to dehydrate finally with alcohols in which eosin was dissolved.

The capillaries of the injected material were perfectly traceable in section, which is not possible with low magnifications in uninjected material, beyond perhaps the earliest stages. Two dimensional reconstructions were made of those vessels which had already attained definitive form. Some difficulty was at first experienced in determining the relationship between the dimensions of successive sections, the process spoken of by PETERS (1906) as " Richtzeichen." One method tried was that of using a profile drawing of the particular embryo in question as a base line during the subsequent reconstruction. This was not found satisfactory. Eventually, the method adopted was that of fixing the main outlines of the reconstruction during the process of section cutting ; in other words, of reconstructing from the uncut surface of the block.

A microscope with squared eye-piece was arranged to view the block when in position on the microtome, so that after each section had been cut, the surface of the next section could be viewed, still forming part of the block. The dimensions along a vertical plane of the external profile and of such organs which could readily be observed under these conditions was plotted to scale against the number of sections cut, thus furnishing a preliminary reconstruction. When the sections were mounted, the reconstruction was proceeded with, using the same optical arrangements which had previously been employed. The advantage of this method of reconstruction for paraffin sections is that whereas a certain amount of distortion of the section during the process of cutting and mounting is inevitable, one is here fixing the main outlines of the reconstruction from the undistorted block. One can therefore gauge the amount to which distortion has taken place, and, allowing for it, a finished reconstruction of any required series of structures can be produced in relationships as natural as the processes of fixation and dehydration permit.

General review of previous work

Miss SABIN has given an account, which is summarized in the next section of this present communication, of the blood vessels of the chick from the earliest stages to that of twenty-nine somites. Otherwise, the only work on the vascular system of the chick in which injected material has been employed is that of TWINING (1906). He is primarily interested in establishing the true nature of the secondary external carotid in the chick, which, as he shows, is not related to the aortic arches, but is formed from a cross-anastomosis between dorsal and ventral aortæ in front of the third aortic arch.

In this work he corrects the earlier inaccurate accounts of the carotids in the chick, among which is that of KASTSCHENKO (1887). The latter's work is one of the very few in which both arteries and veins are studied. Although in his text he limits his description to the arteries, except for an account of the replacement of the vein medial to the post-otic nerve roots by one lateral thereto. His figures illustrate both arteries and veins, and form the most useful part of his contribution to the subject of the development of the vascular system, interpreted in the light of later work.

The veins of the chick have been studied throughout the whole period of development by VAN GELDEREN (1924), as part of his studies on the comparative embryology of the head sinuses of vertebrates. His account is not a complete one, however, and no reconstructions are given. VAN GELDEREN'S work is summarized at the beginning of the section of the present work devoted to the venous system.

Otherwise, work on the development of the blood vessels of the chick has centred on some particular feature. There is a series of studies on the subclavian arteries (SABIN, 1905 ; EVANS, 1909 ; FLEMING, 1926, who is primarily concerned with the Ostrich ; BAKST and CHAFFEE, 1928) and on the vertebral artery (KRASSNIG, 1913 ; FLEMING, 1926), all of which will be reviewed under the sections devoted to these vessels.

Work of the development of the head arteries of birds other than the chick is confined to the work of HAFFERL (1921, *b*) on the plover. The adult distributions of the head arteries of this form appear to resemble very much those of the chick, except that the branch of the stapedial artery which runs into the inferior alveolar canal is connected also with the external carotid, a connection which is absent in the chick. Moreover, the spheno-maxillary artery disappears in the adult plover. HAFFERL describes the penetration of the inferior alveolar canal of the lower jaw by four successive arteries, the Arteria alveolaris inferioris primaria from the ventral aorta, the Arteria alveolaris inferioris secundaria from the stapedial, the Arteria alveolaris inferioris tertaria from the internal carotid through the spheno-maxillary artery, and the Arteria alveolaris inferioris quarternia from the secondary external carotid. This illustrates well the type of description given by workers on uninjected material. Most probably, had HAFFERL'S material been injected, all these four arteries would have been described as one and the same capillary plexus, making contact with different points of the head arterial system at different stages of development.

II—THE ARTERIES

Review of Miss Sabin's Paper (1917)

The development of the blood vessels in chick embryos were studied in detail up to the stage of twenty-nine somites, in early stages by the cultivation of whole blastoderms in hanging drop preparations, and in later by injection technique.

She refers to the original description of His (1900), who derived the blood vessels of the whole embryo from a plexus of cells in the area opaca which he termed "angioblasts," and which are first found at a stage just previous to the appearance of the somites. These, according to His, differentiate into both erythroblasts and endothelium, and the embryo itself is vascularized by centripetal growth of endothelium across the area pellucida.

Miss Sabin describes the angioblasts of the area opaca at the pre-somite stage as a plexus of cells beneath the mesodermal plexus in which the coelom will arise. This ventral plexus aggregates into close masses of cells, the inner of which soon become much vacuolated. The vacuoles soon run together, and thus is formed the lumen of a blood vessel, as is shown in a later paper (Sabin, 1920). The outermost cells vacuolate only at their inner margins, and thus is formed flattened endothelium, which can give rise to blood cells. According to Miss Sabin, the original description of His is incorrect so far as the angioblasts of the area opaca are not the whole source of the endothelium of the embryo, for a differentiation of angioblasts takes place in the axis of the embryo itself. Modern opinion would deny that the vascular tissue of the area opaca contributes to that of the embryo at all, for the theory of local origin of endothelium is almost universally held at the present time (McClure, 1921). Miss Sabin refers to the main sources of evidence for this view, but does not specifically state whether she could see vascular tissue migrating across the area pellucida into the embryo. McWhorter and Whipple (1912), who were the first to study the chick blastoderm *in vitro*, and under high magnifications, describe an independent origin of vascular anlagen in the area pellucida, and make no mention of a centripetal migration.

At the stage of six somites, the dorsal aorta of each side is represented by a plexus of angioblasts running lateral to the myotomes; further forward it has formed a definitive vessel, the lateral heart rudiment lying between endoderm and the inner amnio-cardiac vesicle wall. There is also a plexus of angioblasts running backwards along the hind brain, mesial to the first myotome, and ending caudally opposite the latter. These two longitudinal plexuses are connected by transverse plexuses, one anterior to the first myotome, and the second between the first and second myotomes. In addition, the ventral cephalic aorta is represented by an anterior prolongation of the cardiac primordia, which have met anteriorly in the mid-ventral line.

At the stage of nine somites, the dorsal aorta behind the head fold is a complete vessel and can be injected. The dorsal cephalic aorta is still in the form of a plexus, but by the time the twelve segment stage is reached is a large vessel on each side with branches to fore- and mid-brain, and a single longitudinal channel to the hind-brain. These all, however, end blindly and are difficult to inject. The fore-brain plexus connects with the arch of the aorta, the mid- and hind-brain plexuses with direct branches of the cephalic aorta. Such is the "deep primary plexus" which proceeds to give rise to a superficial plexus opposite fore- and mid-brain, draining the former, and which, when the twenty-nine somite stage is reached has differentiated as the most cranial section of the primitive cerebral vein.

Into this drains the primitive maxillary vein, *V.m.p.*, fig. 1, Plate 1, which receive the marginal vein of the optic cup. At first it is itself drained only by the primitive channel of the hind-brain, *Va.p.r.*, fig. 1, through the transverse vein of the first interspace, and so into the Cuvierian duct. The primitive channel of the hind-brain, otherwise known as the median head vein, runs medial to the ganglia and to the otic vesicle, and in its function as the link between the Cuvierian duct and the drainage channel for the brain is now replaced by a vessel which develops as a plexus between the first aortic arch and the anterior cardinal. This runs lateral and ventral to the median head vein, medial to the trigeminal ganglion, but lateral to the facial ganglion and to the otic vesicle. It is the vessel known as the lateral head vein, and is called by SABIN the second section of the primary head vein *V.cap. p.* 2, fig. 1. The median head vein becomes a capillary plexus which spreads dorsally over the surface of the hind-brain, finally covering it as completely as the fore- and mid-brain are covered.

Continuing the description of the twenty-nine somite stage, the group of capillaries springing from the first aortic arch over the ventral surface of the fore-brain is differentiating on each side into two vessels, one running cranially and the other caudally. These are the future cranial and caudal rami respectively of the circle of Willis on each side. The caudal ramus grows backwards beneath the capillary plexus on the mid- and hind-brain, and meets a vessel growing forwards at the same level. This latter arises from the longitudinal anastomosis of intersegmental arteries, of which the most cranial is in the first interspace. Thus a mid-ventral plexus in the hind-brain arises from which the median basilar artery will be resolved. Small direct branches of the internal carotid to the mid-brain plexus and to the primitive vessel of the hind-brain still persist.

Fig. 1, Plate 1, is reproduced from SABIN's Plate 6, representing a chick embryo of twenty-nine somites.

The aortic arches and internal carotid

KASTSCHENKO (1887), in his work on "Das Schlundspaltengebiet des Hühnchens," studies the development of the aortic arches from their earliest appearance. He finds a difference between the first and the succeeding aortic arches, in that while the latter run between pharyngeal pouches, the second aortic arch running between the first and second, the first aortic arch does not run immediately in front of the first pharyngeal pouch in a direction parallel to that of the other aortic arches. Starting ventrally from a point in front of the first pharyngeal pouch it takes an oblique course forwards in front of this pouch to meet the dorsal aorta in a loop at the base of the fore-brain. Later, according to KASTSCHENKO, another aortic arch is formed in front of the first pharyngeal pouch, parallel with the other arches, by which time the arch running to the base of the fore-brain has disappeared, the section of lateral dorsal aorta connected therewith becoming the internal carotid. KASTSCHENKO would regard both these as true aortic arches, one interpretation among others which he advances being that the anterior one represents a premandibular vessel. Indeed, to any small vessel springing from the lateral dorsal aorta in this region, and running suitably downwards he would assign the status of an arch. Nothing illustrates better than this our change of attitude towards morphological speculation of this nature, consequent upon our ability to study whole mounts of injected material side by side with the reconstruction of sections. To this account of KASTSCHENKO's we can add the following. The first aortic arch appears in the manner described by KASTSCHENKO, not preceded, in common with the other aortic arches, by a capillary plexus, but being formed from angioblasts directly. Towards the end of the second day, however, by which time the second and third arches have appeared, the ventral section of the first arch—that is, from a point directly in front of the first pharyngeal pouch—forwards to the arch at the base of the fore-brain, becomes plexiform, and this plexus is continued dorsally upwards in front of the first pharyngeal pouch to a point immediately behind the trigeminal ganglion where it assists in founding the anastomosis between the anterior cardinal vein and the superficial fore-brain plexus which becomes the lateral head vein, as described in the review of Miss SABIN's paper above. This plexus in front of the first pharyngeal pouch, though primarily connected with the lateral head vein, does connect with the lateral dorsal aorta at this point at a stage a little later than that shown bv Miss SABIN in her Plate 6, here reproduced as fig. 1. At this time the plexus leading forward from this point to the base of the fore-brain, derived from the anterior half of the ventral section of the first arch, disappears, as shown in fig. 3, Plate 2, a drawing of a transparency of an embryo of thirty-two somites. Thus we, seeing a more complete and objective picture of the embryonic vascular system than is possible by the reconstruction of uninjected material, are less inclined to fix on any particular capillary channel, and to invest it with special morphological significance.

Finally, the plexus in front of the first pharyngeal pouch gives rise to a ventral superficial plexus in the mandibular arch, *su.p.m.a.*, fig. 5, Plate 3, with which will be associated the future manibular ramus of the external carotid, *md.r.*, fig. 7, Plate 4, as described below under the section " External Carotid."

A precisely similar plexus arises in the hyoid arch, *su.p.hy.a.*, fig. 5, when the second aortic arch becomes plexiform ; that is, towards the end of the fourth day of incubation. A connection with the lateral dorsal aorta is retained through a single capillary channel running between the second and third pharyngeal pouches, *st.rt.*, fig. 5, which also joins more laterally and dorsally with the lateral head vein. This towards the end of the fifth day of incubation loses its actual connection with the lateral head vein, to run forwards as a single capillary channel immediately beneath the latter. This is the root of the stapedial artery, which thus arises in connection with the second or hyoid aortic arch, corresponding with the orbital artery of fishes, and agreeing with the results of TANDLER (1902) and his school for Amniota.

Serially homologous with the orbital artery in fishes is the ophthalmic artery, given off from the dorsal end of the mandibular arch. The corresponding vessel in the chick cannot, however, be traced to an origin from the plexus in front of the first pharyngeal pouch. The ophthalmic arteries of the chick run primarily to the plexus which surrounds the eyeball, and which in the twenty-nine somite stage described by Miss SABIN is referred to as the marginal vein of the optic cup, drained both by the primitive maxillary veins and the first section of the lateral head vein. This marginal vein, having become an extensive plexus round the eyeball, acquires two connections with what is morphologically the arterial system, one with the anterior division of the circle of Willis, *oph.ce.*, fig. 4, Plate 2, and the other with the internal carotid itself, *oph.i.c.*, fig. 4, at a point just where the latter gives off the anterior and posterior rami of the circle. Now these anterior and posterior rami originate as a cloud of capillaries given off from the first aortic arch. Thus the ophthalmic artery which arises at this point, which we may term the " internal carotid ophthalmic " is in the position of the early first aortic arch, and not in that of the later plexus in front of the first pharnygeal pouch.

The other ophthalmic artery I have called the cerebral ophthalmic. Both are shown in fig. 4, a drawing of a chick embryo of thirty-two somites, in which the ink has lodged in the arteries, rather than in the veins or plexuses. Both ophthalmic arteries run directly to the marginal plexus of the optic cup, a direct connection in both being traceable up to the stage of four and a half days, when they join in a ring around the inner margin of the iris, as shown in fig. 7, Plate 4. Their proximal sections which run within the orbit are found medial to the oblique, but lateral to the recti muscles. The internal carotid ophthalmic runs round the anterior surface of the ciliary ganglion to its position lateral to the recti. At six days, the ophthalmics are vessels which supply the interior of the orbit, rather than the orbit itself. The internal carotid ophthalmic runs round the ciliary ganglion to divide into two vessels, one of which runs upwards lateral to the rectus externus, and soon joins with a branch of the stapedial which will arch over this muscle in running from the medial to the lateral side thereof. The other branch of the internal carotid ophthalmic will soon anastomose with the distal part of the cerebral ophthalmic. At eight days, both these anastomoses have been accomplished.

LILLIE (1919), in his book on " The Development of the Chick," states that no central retinal artery is found in birds. This conclusion I am able to confirm for the chick. A central retinal artery, where present, arises as a connection between the blood vessel of the choroid fissure, and the internal carotid ophthalmic. In the chick, the former is a branch of the primitive maxillary vein, *v.ch.f.*, fig. 5, Plate 3. Arterial blood appears to reach the interior of the eyeball in the chick at hatching through a number of small branches of the ophthalmic trunk in the orbit, which run through small foramina in the sclerotic.

Topographically described, the branches of the internal carotid running forwards from behind in the adult are as follows : the external carotid, the stapedial, the palatine, the spheno-maxillary, the ophthalmic, and the cranial and caudal rami of the circle of Willis. Forwards from where the stapedial is given off, the internal carotid runs inside a bony canal in the basitemporal, along with the carotid vein and a sympathetic nerve. The palatine branch of the facial runs at first outside the cartilage of the auditory capsule surrounding the lagena, then through the basitemporal to the internal carotid canal. It crosses and touches the sympathetic nerve of the carotid canal, and continues to accompany the palatine artery, which is given off at this point. A very short distance further forward is given off the spheno-maxillary, which is accompanied for a short distance by the forward continuation of the carotid sympathetic nerve, which soon leaves it as the spheno-maxillary artery curves ventralwards. As the carotid canal in this region lies superficially in the basitemporal, these arteries are outside the latter as soon as they are given off.

Hafferl (1921, *a*) concludes from his studies on the development of the head arteries in the gecko and on the plover (Hafferl, 1921, *b*) that the palatine or vidian artery accompanying the pharyngeal branch of the facial to which these names are applied, is either a derivative of the dorsal end of the first aortic arch, or arises in that region, namely, in front of the first pharyngeal pouch. In the plover, the spheno-maxillary artery is given off a short distance in front of the vidian. It joins with various branches of the external carotid during embryonic life, but disappears in the adult.

Careful examination of the five and a half day stage in the chick fails to reveal any branch of the internal carotid accompanying the palatine branch of the facial in front of the first pharyngeal pouch. The roof of the pharynx is clothed with a somewhat loose plexus, but this is not specially related to the palatine nerve.

At the six and a half day stage, however, the spheno-maxillary artery has appeared as a well-differentiated vessel running down to the maxillary ramus of the external carotid, *sph.-m.a.*, fig. 16, Plate 9, while just behind the palatine nerve is invested with a plexus of very fine capillaries. This is true also of the seven and a half day stage, the palatine artery acquiring a definitive form at about the nine day stage. Shortly afterwards it is accompanied also by a vein.

If all branches of the internal carotid in front of the first pharyngeal pouch are to be regarded as morphologically arising from the dorsal end of the first aortic arch, the palatine, the spheno-maxillary, the internal carotic ophthalmic, and all the encephalic vessels will be included. Indeed, the only direct evidence we have concerns the latter, which as Sabin has shown, definitely do arise as a plexus springing from the arch of the mandibular aorta. The conception of segmental position in the vertebrate head later than a stage corresponding to the four day chick, does not appear to the writer to be fruitful. Beyond such a stage a much more potent force in the attainment of definitive form is the tendency towards association between nerves and blood vessels. The palatine branch of the facial belongs morphologically to the hyoid somite, and yet the factors determining the form and position of the palatine artery must be identical with those affecting the nerve.

Anterior to the spheno-maxillary artery, the internal carotid enters the pituitary fossa, gives off the internal carotid ophthalmic, which runs through a foramen in the wall of the pituitary fossa, and then divides into the caudal and cranial rami of the circle of Willis.

The encephalic arteries of the adult fowl have been described by **Hofmann** in his comparative account of the head arteries of vertebrates (**Hofmann**, 1900). For birds, he first describes the encephalic arteries of the duck in detail, and then points out to what extent Gallus, Turdus, and Corvus differ in this respect from Anser. To his account of Gallus I have not much to add. The main trunk of the cranial ramus describes an almost complete circle about the optic chiasma, incomplete, however, antero-medially where on each side the cranial ramus divides into an upper and a lower branch. The upper branch is the anterior cerebral artery, which runs upwards between the medial surfaces of the cerebral hemispheres. The anterior cerebral arteries of each side, according to **Hofmann**, are connected by numerous cross-anastomoses, although birds, unlike mammals, are said to have the circle of Willis incomplete anteriorly. The lower branch is referred to in this paper as the " cerebral ophthalmic," and is called by **Hofmann** the " ethmoidal artery." As described above, the root of the cerebral ophthalmic is the root of a vessel which in earlier stages runs to the eyeball, and only later makes connection with the artery running down the olfactory nerve (my ethmoidal artery), which in its turn acquires a connection with the stapedial system.

Proceeding caudally, the next branch of the cranial ramus of the circle of Willis to be given off is the middle cerebral. This in Gallus runs anteriorly rather than laterally, and the laterally running vessel of Anser which runs in the Sylvian fissure, and to which this name is applied, is represented in Gallus by a small branch of the middle cerebral running laterally in this fissure. In my material I have found the anterior choroid plexus to be supplied by a vessel which is either a branch of the middle cerebral, or is given off from the cranial ramus of the circle of Willis immediately behind the middle cerebral. According to **Hofmann**, the anterior choroid plexus is supplied by the posterior cerebral.

The posterior cerebral is given off from the cranial ramus of the circle of Willis at the most lateral point of its sweep round the optic chiasma. It runs immediately upwards close to the brain stem, and hidden from external view both by the hinder part of the cerebral hemisphere, and the anterior part of the optic lobe, between which its course lies. It gives off a number of small branches to these two structures as it runs upwards, and reaching the dorsal surface of the brain divides into a cranial and a caudal ramus. The cranial rami run forwards between the cerebral hemispheres, and according to **Hofmann** those of both sides unite to form a median vessel in Anser and Gallus, though not in Turdus, which may, however, be supplied by the anterior ramus of one side only. In my material, I have not found the anterior rami of the posterior cerebral to fuse. The caudal ramus runs to the cerebellum, in an asymmetrical fashion, the asymmetry of the caudal ramus bearing no relation to that of the cranial.

Still proceeding caudally, the next encephalic artery to be encountered is the bigeminal (Arteria lobi optici of **Hofmann**). This, in Anser is given off from the caudal ramus of the circle of Willis, in Turdus from the cranial, and in **Hofmann**'s figure of Gallus appears to be given off at the point where caudal and cranial rami separate. In my material I have found the bigeminal artery to develop always from the caudal ramus, and in one instance only, namely, the chick at the hatching stage, fig. 23, Plate 9, to come off from the cranial ramus. The bigeminal artery is distributed to the lower surface of the optic lobe, and to the cerebellum, where it anastomoses with the caudal ramus of the posterior cerebral.

The variability of its origin illustrates a principle which I have found to hold in all instances of variability within the encephalic vessels which I have studied. The principle is this. When variability is encountered among the adults of a number of different birds, then in the intensive study of a large number of specimens of any single species, precisely the same feature will be found to be variable. The most striking example of this has been in the relations between the caudal rami of the circle of Willis and the basilar artery. HOFMANN states that the basilar artery in Anser and Gallus is given off from both caudal rami. The same condition is described by BEDDARD (1905) for Gymnorhina. The latter author further states that in the ostrich the contribution to the basilar from the left caudal ramus is much larger than from the right; in the penguin, the basilar is "given off" entirely from the left. We can compare these data with those which have emerged from the present study of Gallus, where since the circle of Willis is as complete at the three day stage as it is in adult life, most of the developmental material will be suitable for providing data on this question.

Up to the three day stage, the basilar is always formed equally by both left and right caudal rami. Of five embryos between the stage of four and five days of incubation, all are asymmetrical in this feature, four having a basilar supplied by the left caudal ramus, and one by the right. Of four embryos between the stages of five and a half and seven days, three are "lefts" and one a "right." The same is true of four embryos between seven and a half and eight days. Of the remainder, a nine and a half day embryo, and a hatched chick are "lefts," and a twelve day and an eighteen day embryo "rights." The adult of Gallus described by HOFMANN is symmetrical with regard to the origin of the basilar. The number of examples studied is too small both from the comparative side and from within the species Gallus domesticus to attempt any statistical analysis, yet perhaps we may note a tendency for the predominance of the sinistral condition in both.

The basilar artery, however related to the caudal rami of the circle of Willis runs backwards as a median vessel along the mid-ventral surface of the medulla and spinal cord, showing a tendency to retain its original paired condition for short stretches opposite the spinal nerves, where arteries are given off which correspond with the latter, and which are derived from anastomoses with the original series of intersomitic arteries. These I have found very difficult to trace in later stages, as much of my later material was uninjected, although HOFMANN finds them in the adult much as in my earlier stages. They must, however, be very unimportant channels for the transmission of arterial blood in the adult.

The basilar artery further gives off a series of small vessels to the ventral surface of the medulla which HOFMANN states are metamerically arranged, although neither his figures nor my material confirm this statement. A large vessel, the cerebellar, is given off just in front of the root of the abducens. It runs laterally to give off a branch to the restiform body and the posterior choroid plexus, and runs sharply round the flocculus where it is closely related to a vein coming from this region, to reach the upper surface of the cerebellum.

A striking contrast exists between the relative time of formation in ontogeny between the encephalic arteries and the encephalic veins. Whereas the anlage of the circle of Willis is recognizable at the twenty-nine somite stage, and all the arteries of the brain can be recognized at seven and a half days of incubation, considerable progress still remains to be made in the development of the head sinuses at the nine day stage.

The first encephalic artery to be differentiated is the bigeminal, which can perhaps be correlated with the precocious development of the optic lobes in birds. In Miss SABIN's drawing one of the twenty-nine somite stage, reproduced here as fig. 1, Plate 1, the plexus over the anlage of the optic lobes can be seen to be concentrating into a vessel running up towards the dorsal surface of the mid-brain. In a thirty-two somite embryo, this vessel can be recognized still more clearly, *bi.a.*, fig. 4, Plate 2, due in part to the fact that the injection mass has not lodged in the finer meshes of the fore- and mid-brain plexus. This vessel is the bigeminal artery. As in Miss SABIN's twenty-nine somite embryo, the plexus growing back over the hind-brain has anastomosed with the first five intersomitic arteries.

This anastomosis takes place by growth of a capillary forwards and backwards from each intersegmental artery along the ventrolateral surface of the spinal cord. At the early four day stage, drawn in fig. 5, Plate 3, many intersomitic arteries can be seen to be undergoing this process, which by the four and a half day stage has affected the whole series, and a close plexus invests the whole spinal cord, except in the mid-dorsal region. It is at this stage that the central nervous system, till now a non-vascular area, is penetrated by capillaries. There is now a definitive basilar artery beneath the hind-brain, which is single and median as far back as the level of the vagus, caudal to which it is paired. It gives off into the ventral surface of the hind-brain and spinal cord a row of tiny capillaries on each side of the mid-ventral line separated from each other by a distance equal to that which separated the paired basilar trunks caudal to the vagus, yet which anterior to the latter run forwards at the same distance apart, formed presumably at a time when the basilar was paired in this region also. The interval between two successive penetrating capillaries on either side appears to be constant, and at no time to bear a segmental relation, either somitic or neuromeric. An intersomitic distance would correspond to about eight such intervals. Penetration has commenced by this time in the fore- and mid-brain also, but is most conspicuous as yet in the hind-brain and spinal cord. By the five and a half day stage, the capillaries within the central nervous system can be seen everywhere concentrating in a layer immediately superficial to the ependyma. Through the marginal velum run capillary channels arranged always in a radial manner to the plexus between ependyma and velum. Along the hind-brain and spinal cord, these radial capillaries are no longer restricted to two lines of penetration, as in the four and a half day stage. This description of the capillary system within the central nervous system holds good up to the six or seven day stage, when the plexus surrounding the ependyma becomes somewhat diffuse, and invests the latter less closely. Further observations on the development of the vascular system within the brain have not been made.

The basilar artery is formed by the coalescence in the mid-line of medial offshoots of the hind-brain plexus. At the thirty-two somite stage of fig. 4, Plate 2, the internal carotid divides at the base of the fore-brain into the cranial and caudal rami of the circle of Willis, more or less in definitive form, and the latter at once gives off the bigeminal artery, and then runs backwards along the ventral surface of the hind-brain, those of each side running parallel, connected by irregular cross-connections, and finally anastomosing with the anterior intersomitic arteries as described above. Thus at this stage both caudal rami contribute to the formation of the basilar. The divergences from this condition experienced in later stages have already been described.

At the stage of five and a half days, the basilar is well differentiated as a median vessel as far caudally as the level of the vagus, behind which it is a paired vessel increasingly more difficult to distinguish from the general plexus on the ventral surface of the spinal cord as one passes caudally. All the intersomitic arteries have anastomosed with this plexus. Numerous lateral branches are given off from the basilar, particularly in the region of the auditory capsule, some of which are given off in front of the root of the abducens.

The cranial ramus of the circle of Willis is represented by a differentiated vessel which turns downwards at the level of the posterior border of the cerebral ophthalmic, gives off the cerebral ophthalmic, and then runs forwards and medially to divide on each side into two vessels of which one runs lateral, *ext.eth.a.*, fig. 8, Plate 4, and the other medial, *int.eth.a.*, fig. 8, Plate 4, to the olfactory invagination. These are the future external and internal ethmoidal arteries respectively.

At the seven and a half day stage, the interorbital septum has increased in depth, concomitant with which change there has been an elongation both of the olfactory nerves and of the ethmoidal artery, the vessel which accompanies the olfactory nerve to divide into the internal and external ethmoidal arteries. The proximal section of the ethmoidal artery now connects with the supraorbital ramus of the stapedial, *st.sup.*, fig. 16, Plate 9, and has at this stage no connection with the cranial ramus of the circle of Willis. Both posterior, middle, and anterior cerebral arteries have differentiated. The posterior cerebral runs upwards to divide into anterior and posterior rami, the middle cerebral runs forwards along the lateral surface of the cerebral hemisphere, and gives off at its base the vessel which will supply the anterior choroid plexus, as yet a few simple folds of the dorso-medial wall of the cerebral hemisphere. The cerebellar artery has differentiated as a lateral branch of the basilar immediately in front of the abducens root ; it runs obliquely upwards behind the root of the acustico-facialis.

At the nine day stage and beyond, the encephalic arteries are practically in their adult condition. The ethmoidal artery has re-acquired a connection with the system of the cranial ramus of the circle of Willis, *eth.oph.ce.*, fig. 20, Plate 12, by means of an anastomosis with the cerebral ophthalmic whose proximal portion has anastomosed with the ophthalmics of the internal carotid and stapedial. With the atrophy of the middle section of the cerebral ophthalmic connecting these two systems, the root of the cerebral ophthalmic appears to form the root of the ethmoidal artery, *eth.oph.ce.*, fig. 23, Plate 9.

By the nine day stage, the anterior choroid plexus is well developed, and the branch of the cranial ramus which supplies it has attained an equal stage of development, *mid.c.a.c.p.*, fig. 20. The attainment of the fully differentiated condition of a vessel is always linked with the differentiation of the organ which it supplies. Thus the cerebellar artery only attains the adult form later than the twelve day stage, at which time the flocculus is still membranous, and the posterior choroid plexus still in a simple condition. We have as yet, however, no evidence to indicate which of these two differentiations, namely, of organ and of blood vessel supplying that organ, is to be regarded as the causative factor.

The external carotid

The term " external carotid," used in a wide variety of senses in vertebrate morphology, belongs primarily to the ventral aorta. This condition of the external carotid, the permanent one of the squamata, is superseded in the birds by the atrophy of the proximal region of the ventral aorta and the acquirement of a cross-connection between the dorsal and ventral carotids, which becomes the permanent root of the external carotid. The nature of this cross-connection was misunderstood until the work of TWINING (1906) who showed that it was not the remains of an aortic arch, but a new vessel arising from the dorsal carotid just behind the stapedial (auricular of TWINING) and at about six days of incubation joining with the ventral carotid. Essentially the same results were obtained by HAFFERL (1921,*b*) in his study of the development of the head arteries of the plover, who suggested that the secondary external carotid root was a ventral branch of a segmental artery.

The development of the external carotid in the ostrich was studied by FLEMING (1926) who in addition reinvestigated that of the chick. His thesis was that in both birds, the secondary external carotid originated as a capillary which arose from the dorsal end of the third aortic arch and ran forwards along the internal carotid to its final position along that vessel, there to anastomose with it. By the atrophy of the proximal part of this capillary, and the downgrowth of its distal part to join with the ventral aorta, the secondary external carotid was established. To this subject we shall return later.

TWINING is primarily interested in establishing the nature of the secondary external carotid, and has not apparently studied the individual branches thereof, although most of them are indicated in his figures. Consequently, something remains to be added to his description. Moreover, the earliest embryo studied by him is of four and a half days of incubation.

It is not possible to speak of a ventral aorta until the continuity of at least the first aortic arch has been interrupted, since the first three aortic arches lie immediately dorsal to the distal end of the truncus, from which they take origin. Thus from a period a little later than the twenty-nine somite stage described by Miss SABIN (1917), the ventral aorta is represented by the ventral end of the first aortic arch, the capillary plexus which resulted from the degeneration of the latter having been interrupted, as described above. Next appears a plexus of capillaries occupying a superficial position in the mandibular arch extending from the level of the ventral aorta downwards and inwards, those of the two sides meeting in the mid-ventral line, *su.p.m.a.*, fig. 5, Plate 3. A similar plexus makes its appearance in the hyoid arch when the second aortic arch degenerates, *su.p.hy.a.*, fig. 5. These superficial plexuses of mandibular and hyoid arches are a very characteristic feature of injected embryos of from three and a half to four and a half days of incubation. Later, at about five days, they merge with one another, and form a system of superficial capillaries in the ventral region of the neck.

In the review of Miss SABIN'S 1917 paper, it was stated that she showed that the lateral head vein developed first as a capillary plexus between the first aortic arch and the anterior cardinal. When the first aortic arch degenerates, parts of this capillary plexus persist with the result that the superficial plexus of the mandibular arch is connected both with the dorsal carotid and with the lateral head vein. The same is true of the hyoid arch, and here the connection with the dorsal carotid persists as the root of the stapedial artery, *st.rt.*, fig. 5. Thus the stapedial artery belongs morphologically to the dorsal end of the second arterial arch, a point on which all workers on cephalic arteries are agreed. Later, at the five and a half day stage, when the superficial plexuses in mandibular and hyoid arches have merged, a further connection between the hyoid plexus and the dorsal carotid can be made out, behind the root of the stapedial, and immediately in front of the glossopharyngeal nerve, *sec.ext.c.rt.*, fig. 8, Plate 4. This will become the secondary external carotid root.

Fig. 5 is a drawing of an early four day stage which shows the mandibular and hyoid superficial plexuses. In the mandibular plexus a single capillary leads laterally into the region of the maxilla, where it soon forms an extensive plexus. Fig. 7, Plate 4, represents a four and a half day embryo in which the ink in the ventral aorta has lodged in the main vessels supplying the capillary plexuses, rather than in those plexuses themselves. We thus see that the ventral aorta ends in two branches, one running into the maxilla, *mx.r.*, and the other into the mandible, *md.r.* This is the primary form of the external carotid, and all subsequent branches can be related either to the maxillary or the mandibular ramus. Proximally in addition, a plexus surrounds the thyroid at the base of the third aortic arch, out of which later will be formed the definitive thyroid artery.

In a reconstruction, it is impossible to represent more than these main rami, and the plexuses themselves must pass unrepresented. However, where it is possible to examine whole embryos in transparency, comparison of the results obtained by the two methods gives us a full and complete picture. The latest stage in which much can be seen by transparency is that of five and a half days. However, after this stage emphasis shifts naturally from plexuses to definitive vessels, and indeed in any later stage it would be an almost impossible task to describe every capillary in the head. Nevertheless, it has been found possible to recognize the antecedent plexus of many vessels which arise subsequent to five and a half days, although they are not represented in the reconstructions. Moreover, in the latter, a plexiform vessel is represented in the same manner as a definitive artery or vein. Due recognition of these differences, however, is made in the text.

In the reconstruction of the five and a half day chick, fig. 8, Plate 4, it will be seen that the mandibular and maxillary rami of the external carotid are essentially the same as in the four and a half day stage, but that they point forwards instead of downwards. This is correlated with the fact that at this time the mandibular arches swing forwards and come to lie inside the maxillæ. In a six and a half day embryo, chondrification of the visceral skeleton has taken place, and the relationship of the two rami of the external carotid to the " hyoid apparatus " can readily be made out. The junction of maxillary and mandibular rami is medial to the ceratobranchial, along the dorsal edge of which the mandibular ramus runs forward for some distance. The ceratobranchial then joins the basibranchials, and the mandibular ramus then takes a more ventral course, joining everywhere with a superficial plexus in the tongue rudiment, the forerunner of the lingual artery.

By the six and a half day stage, however, the secondary external carotid root has been established, *sec.ext.c.rt.*, fig. 14, Plate 7. It was mentioned above that this is originally a tiny branch of the dorsal carotid behind the root of the stapedial and immediately in front of the glossopharyngeal which runs to the superficial hyoid plexus. By further rotation forward of the mandibular arches, the junction of the maxillary and mandibular external carotid rami comes very near the dorsal carotid, and it is then that the anastomosis takes place. Thus the secondary external carotid root appears to give off immediately in front of the glossopharyngeal a maxillary and a mandibular ramus, the latter of which is joined to the base of the third aortic arch by the proximal half of the ventral aorta. The relationship of the external carotid to the main trunk of the glossopharyngeal is such that the maxillary ramus is morphologically medial, and the mandibular ramus lateral thereto. Variations of this arrangement which are encountered will form a subject of discussion later.

It is at this time that the backward migration of the aortic arches, dealt with in detail later, is in full swing. One result of this is that the future secondary subclavian artery, until now a plexiform vessel running from the ductus Cuvieri to the ventral aorta, *sec.sub.*(1), fig. 5, Plate 3, running into the latter just in front of the thyroid artery, loses its connection with the ductus and is carried back to the level of the pectoral limb, *sec.sub.*(2), fig. 16, Plate 9. A further result of this process is that while the dorsal carotid increases suitably in length to maintain its connection with the arches, the ventral carotid is unable so to do, and breaks in the middle, the anterior half forming the descending œsophageal artery springing from the mandibular ramus of the external carotid, the posterior half forming the ascending œsophageal artery coming off from its original position at the base of the third aortic arch.

The conclusion reached by FLEMING—namely, that the secondary external carotid root originates from the dorsal end of the third aortic arch thus recapitulating an origin now seen as the permanent one of the Dipnoi, and grows forward along the dorsal carotid to this final position—has been alluded to above. This I have not been able to confirm. Certainly it is true that the secondary external root can be traced backwards for a short distance at the five and a half day stage and indeed later, *sec.ext.c.rt.*, figs. 8 and 14, Plates 4 and 7, but this has not been found possible at an earlier stage, as FLEMING has stated. The feeling of the writer is that theoretical speculation of this nature depending on the existence of a single capillary is only permissible when every capillary in the particular region in question has been studied and described, and this FLEMING, who works with uninjected material, fails to do.

We must now describe the external carotid of the adult fowl, figs. 23 and 31, Plates 9 and 16. The common carotid branches into internal and external carotids at the level of and medial to the glossopharyngeal ganglion. The external carotid immediately gives off the occipital artery whose origin is so close to the internal carotid that GADOW in BRONN's "Tierreich" describes it as a branch of the latter. The occipital artery runs upwards medial to the vagus and lateral to the hypoglossal, gives off branches which supply the neck muscles, *occ.a.l.*, fig. 23, and runs medially to form the root of the vertebral artery, *occ.a.v.*, fig. 23, entering the vertebral arterial canal with the cervical sympathetic nerve, just anterior to the first spinal ganglion. I am unable to trace a connection between the occipital-vertebral artery system and that of the encephalic arteries. Such a connection exists in earlier stages, when medially directed branches of the intersomitic arteries anastomose with the basilar. With the degeneration of the intersomitic vessels, such a connection is lost. Two branches are given off near the base of the occipital artery, one posteriorly, the vagus artery, *v.a.*, fig. 31, Plate 16, running along the ventral side of the main trunk of the vagus, the other anteriorly, a branch which runs forwards and inwards to the median occipital vein, *occ.a.m.*, fig. 31.

The next branch to be given off by the external carotid is the hyoid artery, *hy.a.*, fig. 31, which runs upwards, lateral to the glossopharyngeal and vagus to supply the distal part of the geniohyoid muscle, which envelops the posterior cornu of the hyoid. Next is given off a vessel which is the mandibular external carotid ramus. It gives off a branch, the superior laryngeal, *s.l.a.*, fig. 31, which accompanies the laryngeal branch of the glossopharyngeal, and the laryngeal vein, to the larynx and which gives off the descending œsophageal artery, *d.o.a.*, fig. 31. The continuation of the mandibular ramus, the internal mandibular artery pursues a course similar to that described for the mandibular ramus at an earlier stage. It gives off the lingual artery, *li.a.*, fig. 23, which runs upwards into the tongue.

Next, several arteries are given off together. One, the auricular,* *au.a.*, fig. 31 (temporal of HAFFERL), runs upwards immediately in front of the depressor mandibulæ to the temporal region. It is accompanied by the post-quadrate external facial vein, *ext.f.v.*, fig. 24, Plate 10. Another upwardly directed artery is the external facial, which arches upwards and forwards to give off a vessel which runs upwards with the pre-tympanic connective between the primary and secondary head veins, *p.t.c.*(2), fig. 24, and then itself runs from the medial to the lateral anterior surface of the quadrate, accompanied by the pre-quadrate external facial vein. The artery reaches the superficial aspect of the face, and runs forwards to the region of the nasal capsule, and then upwards towards the frontal region. GADOW, in his general account of the head arteries of birds, states that the external facial artery anastomoses with the ethmoidal artery, but I have not found this so in the chick.

The remaining branches of the maxillary external carotid ramus run between the pharyngeal lining and its glands, and the innermost division of the adductor mandibulæ. I have called them the upper, middle, and lower internal maxillary arteries respectively. The upper division, *int.mx.u.*, fig. 31, runs straight to the palatine glands, the middle, *int.mx.m.*, fig. 31, is the main maxillary external carotid ramus of earlier stages, since it receives the spheno-maxillary artery from the internal carotid. The spheno-maxillary artery runs downwards with the maxillary vein, *mx.v.*, fig. 24, between the internal and external pterygoid divisions of the adductor mandibulæ, and loops underneath the internal pterygoid muscle to reach the middle internal maxillary artery, which as stated above runs medial to the muscles.

No branch of the external carotid in the chick enters the inferior alveolar canal, the inferior alveolar artery being entirely stapedial in origin.

Figs. 26 to 31, Plates 13-16, are a series of reconstructions of the external carotids of chick embryos ranging in age from six and a half days of incubation to hatching. They are intended to show the type of variability which occurs in the relations between arteries and nerves, and also to indicate the stages at which the various external carotid branches acquire a definitive form. The six and a half day embryo of fig. 26 in which the secondary external carotid connection is very recent, has the maxillary and mandibular rami still in a plexiform condition. A single capillary channel leading upwards and backwards behind the glossopharyngeal and vagus represents the occipital artery, and the descending œsophageal artery is represented by the distal half of the severed ventral aorta. The seven and a half days stage of fig. 27, Plate 15, is exceptional in that while the maxillary ramus is medial, and the mandibular lateral to the glossopharyngeal, the union of the two takes place behind the latter. In this figure is shown the rudiment of the auricular artery, and the branch of the glossopharyngeal which supplies the geniohyoid, here medial to the mandibular ramus.

---

*GADOW's name " auricular " is retained for this vessel in preference to the term " temporal," as the latter is best applied to the branch of the stapedial in the temporal region.

Figs. 28 and 29, Plates 13 and 15, show respectively the left and right sides of a nine day embryo in which by now all the main branches can be recognized. On the right side, the glossopharyngeal after leaving its ganglion divides into two, running to either side of the maxillary ramus. The medial division gives off the branch to the geniohyoid. They reunite below the maxillary ramus, and run medial to the mandibular ramus. On the left side of this embryo, the glossopharyngeal runs entirely medial to the whole external carotid, and the only nerve other than the hypoglossal, lateral thereto is the vagus cross-connection, which here runs into the glossopharyngeal below the maxillary ramus.

Figs. 30 and 31 represent respectively the external carotids of a twelve day embryo, and of a chick at hatching. They differ in only one point. In the twelve day embryo both the hyoid artery and the mandibular ramus are given off ventral to the glossopharyngeal branch to the geniohyoid, while in the hatched chick both vessels are dorsal to the latter. A discussion of these results will follow later, the thesis being upheld that the variability of nerves and blood vessels is of the same kind.

The stapedial artery

The stapedial artery of the chick at hatching—The internal carotid, after giving off the external carotid enters a bony canal, the entrance to which lies between the cartilage of the auditory capsule surrounding the lagena and the basitemporal ossification lateral thereto, *st.a.*, fig. 25, *right side*, Plate 14. This canal runs in the basitemporal to the pituitary fossa ; before entering the latter, however, the internal carotid gives off the stapedial. This artery runs vertically upwards behind the exoccipital for some distance, and then pierces the tympanic wing of the exoccipital to come immediately against the hinder wall of the tympanic cavity. It runs upwards and over the tympanic cavity, finally passing medially to the otic process of the quadrate, through the cranio-quadrate passage to the temporal rete. It is accompanied by the descending hyomandibular branch of the facial, as well as by the chorda tympani forwards from the facial root. A vein also accompanies the stapedial, the V. auris interna, the posterior section of the primary head vein dorsal to the tympanic cavity, *p.St.*(2), fig. 24, Plate 10.

The temporal rete lies medially to the temporal muscle, the outermost section of the adductor mandibulæ, and laterally both to the so-called alisphenoid and that section of the adductor originating therefrom. All branches of the trigeminal, except the ophthalmic, run through the rete, these relations of which are shown in fig. 25, Plate 14. This figure is a drawing of a section through the head of a chick at this stage, at a level indicated in the reconstructions of the same series of sections, figs. 23 and 24, Plates 9 and 10, in which the outline of the rete is indicated. All the branches of the stapedial issue from the rete, as well as the following veins : the descending anterior portion of the primary head vein, *p.St.a.*(2), fig. 24, running with the inferior alveolar branch of the stapedial, *st.alv.*, fig. 23, and a vein issuing from the anterior dorsal corner of the rete running with the ophthalmic branch of the stapedial, *oph.st.*, fig. 23, over the rectus externus to the head vein in the orbit, The branches of the stapedial issuing from the rete are the temporal, *st.te.*, fig. 23. the supraorbital, *st.sup.*, fig. 23, the infraorbital, *st.inf.*, fig. 23, and the two which have just been mentioned in connection with their accompanying veins, the ophthalmic and the inferior alveolar. The main stem of the stapedial runs forward through the rete, giving off a branch which divides into two. Of these two, one runs upwards and outwards into the temporal muscle, and the other continues downwards into the rete. In earlier stages this latter can be traced in direct continuity with the inferior alveolar branch of the stapedial which runs with the inferior alveolar division of the trigeminal into the lower jaw canal. In the chick, no connection can be found between this artery and the external carotid system.

The main stem of the stapedial continues to run forward, and enters the orbit through a foramen in the wing of the alisphenoid which delimits its posterior margin. Once in the orbit, this vessel divides into two ; one branch, the ophthalmic of the stapedial, turns sharply inwards, and the other runs directly upwards and over the orbit forwards, accompanied for a considerable distance by a branch of the trigeminal which runs upwards to an eyelid muscle. This supraorbital branch of the stapedial is accompanied distally by a vein, the morphology of which will be described in the section devoted to veins. The artery follows the eyeball forwards and downwards, and running medial to the eye muscles anastomoses with the ophthalmic branch of the anterior cerebral. The united vessel then follows the path of the olfactory nerve distally forming the section to which the term ethmoidal artery is applied, and meeting the nasal capsule, divides into an internal ethmoidal artery which enters the latter, and an external which runs lateral thereto.

One branch of the stapedial remains to be described, the infraorbital. Of that part of the trigeminal which runs immediately lateral through the rete, part innervates the temporal muscle, and part runs forwards and downwards superficially through the orbit to eyelid muscles. It is accompanied by an artery, the infraorbital branch of the stapedial, which issues from the rete. In earlier stages, a direct connection can be traced between the infraorbital and inferior alveolar branches, which latter in turn directly connect with the main artery. In the chick at hatching, both these direct paths have been obscured by the increase in complexity of the rete.

The first appearance of the stapedial root has already been described. At a time when the continuity of the second arterial arch has been interrupted, and the ventral superficial plexus in the hyoid arch formed, the latter retains a connection with the dorsal carotid through a narrow capillary channel which connects also with the lateral head vein, *st.rt.*, fig. 5, Plate 3, forming a system serially homologous with that in the mandibular arch, which was instrumental in forming the first section of the lateral head vein, as described in the review of Miss Sabin's paper. At the five and a half day stage, the root of the stapedial runs laterally and dorsally over the pharynx to join with the superficial hyoid plexus, but by now the connection with the lateral head vein is superseded by a capillary which runs forward immediately ventral to the lateral head vein, fig. 8, Plate 4. In the region of the hyoid visceral pouch this capillary becomes more lateral to the vein, and receives a branch from a plexus over the otocyst, which represents the temporal artery of later stages. Continuing in its path forward, it runs into an extensive plexus surrounding the maxillo-mandibular root of the trigeminal. This is derived from the general plexus surrounding the brain, which in the hind-brain region has resulted from the breakdown of the median head vein, and has moreover extended over the nerve ganglia, down the main nerve roots for some distance. This is the region in which the future temporal rete will arise.

The stapedial then runs into a plexus which covers the dorsal surface of the orbit, and is gradually extending further forwards over the latter, *st.sup.*, fig. 8. Its course is lateral to the anterior cerebral vein, on to which is later grafted an extension developed from this plexus, as will be described below under the appropriate section. Its main derivative is, however, the supraorbital branch of the stapedial. The supraorbital plexus can be seen towards the end of the fourth day to arise as a forward extension from the now fused superficial mandibular and hyoid plexuses. It is everywhere separate from the plexus which surrounds the eye.

In the seven and a half day stage, reconstructed in fig. 16, Plate 9, the anlage of the temporal rete is seen as a mass of capillaries to either side of the laterally directed branch of the trigeminal, *t.r.*, fig. 17, Plate 8. The inferior alveolar branch of the stapedial is now a definitive vessel accompanying its branch of the trigeminal, and the temporal branch can be seen as a small vessel running upwards and backwards lateral to the auditory capsule, past the mesenchymatous anlage of the temporal muscle, *st.te.*, fig. 16. The main branch of the stapedial runs forward towards the orbit, and turns upwards, there to divide into two. The inner branch is the future ophthalmic branch of the stapedial, but can only be followed as a definitive vessel for a short distance inwards. The outer branch is now a definitive supraorbital branch, and takes a more than semicircular course over the orbit to the ethmoidal region.

In the description of the arteries of the brain above, it was shown that up to the six day stage, the forwardly directed ramus of the circle of Willis takes a course corresponding to that of the middle cerebral of later stages, giving off the cerebral ophthalmic, which by this time has lost direct connection with the eyeball plexus, and is now a vessel running downwards and forwards in the orbit, medial to the superior oblique but lateral to the recti muscles. Up to this stage, the forward continuation of the anterior internal carotid ramus then descends to the region of the olfactory nerves, there to divide into a branch running medial to the olfactory sac, and into another lateral thereto. Subsequent to the five and a half day stage, the olfactory nerves elongate considerably, a process directly connected with the growth in depth of the interorbital septum, and the connection between what we may now term the middle cerebral artery and the olfactory system of arteries is broken. A new connection is established between the latter and the supraorbital branch of the stapedial, which has by now extended to the ethmoidal region, *st.sup.*, fig. 16. This apparent continuation of the supraorbital stapedial branch down the olfactory nerves may be termed the ethmoidal artery. By the nine day stage a new cross-connection has developed between the cerebral ophthalmic and the ethmoidal artery a short distance down the olfactory nerves, *eth.oph.ce.*, fig. 20, Plate 12. This runs medial to the only eye muscle which it encounters in this region, namely, the superior oblique, but the main stem running downwards in the orbit is found lateral to the recti muscles, as are all the ophthalmic arteries.

The developing temporal rete now has the form of a dense mass of connective tissue surrounding the laterally running branch of the trigeminal, which at the seven and a half day stage was found to be closely invested with capillaries. These are now becoming larger while retaining their early thinness of wall and irregularity of distribution. Such large capillaries, as we shall see later, play an important part in the development of definitive veins, and to them the term " venule " has been restricted. The inferior alveolar branch of the stapedial is still uninfluenced by the developing rete and gives off a branch which runs down a branch of the lateral portion of the trigeminal to a lower eyelid muscle. This is the infraorbital branch of the stapedial, *st.inf.*, fig. 20. The main stem of the stapedial runs forward through the developing rete, and now at the hinder border of the orbit turns upwards, and gives off in addition to the supraorbital branch at the same sagittal level, the stapedial ophthalmic arching over the rectus externus to unite with the ophthalmic of the internal carotid at a point lateral to the ciliary ganglion. The internal carotid ophthalmic has in addition anastomosed with the distal part of the ophthalmic of the middle cerebral.

By the twelve day stage, the proximal part of the cerebral ophthalmic has disappeared, leaving the distal part as the permanent continuation of the internal carotid ophthalmic, *oph.ce.*(2), fig. 23, Plate 9. The other permanent section of the middle cerebral ophthalmic is the cross-connection to the ethmoidal artery, *eth.oph.ce.*, fig. 23, which appears to run from the middle cerebral to the latter, giving off the anterior cerebral medially. The temporal rete at twelve days still consists of a mass of venules embedded in dense connective tissue surrounding the lateral trigeminal branch. These are now in connection with the descending anterior portion of the primary head vein which has by now lost connection with its post-tympanic section. All branches of the stapedial still run uninterruptedly through the rete.

It has not yet been defined to what extent the inferior alveolar and suborbital branches are influenced by their passage through the rete after the twelve day stage. It is not strictly accurate to speak of their being " interrupted " in their course. If the inferior alveolar branch of the stapedial is followed upwards from below the rete at a stage during the third week of incubation, by which time the arteries are well differentiated from veins by reason of the thickening of the middle muscular coat, it is found that the path upwards into the main trunk of the stapedial is through thick-walled vessels throughout, and, moreover, that this path is a direct one. Numerous small side branches are, however, given off which run into the more abundant thin-walled vessels connected by wide channels with the veins supplying the rete, and which constitute the largest part of the latter. Thus the rete is divisible into arterial and venous parts, everywhere bound up with each other, and connected by narrow channels.

The vertebral and subclavian arteries, and the backward migration of the aortic arches

The first two aortic arches belong to the second and third pro-otic segments, and the third to the first post-otic segment. Yet in an adult Tetrapod the root of the carotid arch is never found in a position immediately behind the auditory capsule but in one many segments behind this region. Clearly, therefore, those aortic arches which are present in the adult must migrate caudally during development.

Before this migration takes place, the embryo is a segmental structure with three sets of segmental organs in undisturbed relations to each other, the central nervous system with its nerve roots, the somites, and the aortic arches. In between the somites are found a series of intersomitic arteries and veins, which at this stage run directly at right angles to the lateral dorsal aorta. When the segmental relations of one of the three series of structures, namely, the aortic arches, are disturbed by backward migration, leaving the other two, the nervous system and the myotomes still undisturbed, the roots of the intersomitic arteries and veins are caused to sever their connection with the lateral dorsal aorta. These vessels anastomose longitudinally with one another ultimately to form the longitudinal vertebral artery which later acquires new connections with the dorsal aorta. Thus the development of the vertebral artery is intimately connected with the attainment of the final position of the aortic arches. It is as equally concerned with the development of the subclavian arteries. The early blood supply to the fore-limb is derived at one stage from a number of branches of the dorsal aorta in intersomitic positions. When that section of dorsal aorta belonging to the intersomitic vessels which supply the fore-limb retreats backwards, a new connection is established with the ventral arterial system.

Intersomitic arteries play a great part in the development of the vascular system. By the fourteen somite stage a series of dorsal projections from the dorsal aorta in between the somites have anastomosed longitudinally to form the common cardinal vein, which acquires a connection with the omphalo-mesenteric vein at the level of the fourth somite at the stage of sixteen somites. This connection is the future duct of Cuvier, and divides the common cardinal vein into an anterior and a posterior cardinal. This is fully described by Miss Sabin, whose bibliography takes note of earlier work in which the origin of cardinal veins from intersomitic arteries is described (Sabin, 1917).

When the stage of thirty somites is reached, the cardinal veins are fully differentiated, and lie lateral to the dorsal aorta. They give off a full series of intersomitic veins, which lie lateral to the intersomitic arteries, and anastomose with them lateral to the spinal cord. These relations are well shown in figs. 1 and 3 of Evans' paper (1909) which are drawings of whole mounts, and in his fig. 4 of a section through a chick embryo of thirty-three somites. My fig. 7, Plate 4, shows the intersomitic arteries and veins at a somewhat later stage, without showing, however, the anastomosis lateral to the spinal cord.

Concerning the development of the primary subclavian artery, namely, that dorsal to the vagus, and arising from the dorsal aorta, I have nothing to add to the description of EVANS, in the paper which is mentioned above, and which may be summarized as follows. In the angle between the duct of Cuvier and the posterior cardinal, a capillary plexus develops, *p.b.p.*, fig. 5, Plate 3, and grows caudally in the somatopleure to a level at which the anterior limb bud will arise, before, however, this has actually occurred. When the somatopleure does thicken in the appropriate position to form the anterior limb bud, a series of outgrowths from the dorsal aorta at this level enter the limb bud, and anastomose with the plexus which has grown downwards in the somatopleure. The outgrowths from the dorsal aorta are in no wise metamerically arranged, but later, at the three day stage those capillaries which spring from the dorsal aorta in other than intersegmental positions atrophy, leaving only those which arise at the same transverse levels as the intersomitic arteries. Thus in such intersomitic spaces, the intersomitic artery will run dorsally, and the segmental subclavian laterally, as shown in EVANS' fig. 4. Segmental subclavians commonly occur in the sixteenth to nineteenth intersomitic spaces respectively. Later, the segmental subclavian of the eighteenth intersegmental space enlarges at the expense of the others, and soon becomes the single dorsal subclavian artery. Considerable variability exists in the development of the primary subclavian artery ; thus in an embryo of three days incubation described by EVANS, the primary subclavian comes off the dorsal aorta between the sixteenth and seventeenth intersomitic spaces, in the four and a half day embryo of my fig. 7, Plate 4, it springs from the base of the artery of the nineteenth intersomitic space.

It is best to refer to the intersomitic vessels by the intersomitic space in which they are found. EVANS states that an artery is found in every intersomitic space except that between somites one and two. In stages of three days of incubation and over, I have not been able to find any arteries in the intersomitic spaces in front of those between the fourth and fifth somites, which gives three intersomitic arteries in front of the first cervical ganglion. The first four somites are cephalic, and early lose their definition, although in a four and a half day embryo from which the reconstruction of fig. 6, Plate 3, was made, I was able to trace the transverse vein of the first interspace, *tr.*1, as well as all the succeeding intersomitic veins. It is clear that the intersomitic vessels between the cephalic somites persist only for a short time, and that no standard of comparison between embryos of different ages will be obtained by counting the series of intersomitic arteries. FLEMING (1926), in his study of the origin of the vertebral and subclavian arteries in the chick and the ostrich, states that the primary subclavian of the chick is formed from the sixteenth intersomitic artery. Should this in his material belong to the eighteenth intersomitic space, it would mean that the first of his intersomitic arteries belongs to the third interspace.

The secondary subclavian artery in the adult springs from the base of the third aortic arch, and lies wholly ventral to the vagus. The most important paper on its development is that by C. G. SABIN (1905). In his summary of previous work on the subject he mentions that of MACKAY, who traced a vessel which appears at the three day stage running from the base of the third arch into the duct of Cuvier. On the sixth day, according to MACKAY, it could be traced into the developing wing. HOCHSTETTER considers this vessel of MACKAY to be a vein draining the base of the hyoid arch. This is also the view taken by SABIN, who was able to see this vessel emptying into the duct of Cuvier in living material of from three to five days of incubation. He states that the ventral subclavian appears first early in the sixth day of incubation, developing in two parts which later unite. The proximal part springs from the ventral end of the third aortic arch on its anterior side, while the distal is an outgrowth of the primary subclavian directed forwards and downwards. The two join, and the middle piece joining them is at first very irregular and traceable only with difficulty. The backward migration of the arches, however, shortens the distance between the primary subclavian artery and the base of the third aortic arch, and early on the eighth day of incubation, the primary subclavian atrophies, leaving the secondary as the permanent source of arterial blood to the wing.

EVANS in his fig. 1 draws a vessel running into the duct of Cuvier in the angle between the latter and the anterior cardinal vein, and labels it " external jugular vein." This is the proximal end of the vein described by MACKAY as running from the base of the hyoid arch into the ductus. I have illustrated it in figs. 3, 5, and 7, *sec.sub.*(1), Plates 2, 3 and 4, which are drawings of transparencies of chick embryos of three, four, and four and a half days of incubation respectively. In the three day stage, it has not yet extended from the ductus as far forward as the level of the hyoid arch, but at four days can be seen joining with the superficial plexus of the hyoid arch, and connected by several capillary channels with the bases of the third, fourth, and sixth aortic arches. Figs. 8 and 9, Plates 4 and 5, are reconstructions of the arteries and veins respectively of a five and a half day embryo, in which this channel now has the form of a definitive vessel, connected with the ventral aorta just in front of the entrance of the latter into the third aortic arch, and with the duct of Cuvier in the angle between the latter and the anterior cardinal. In the six and a half day embryo, whose veins are reconstructed in fig. 11, Plate 6, this channel, *sec.sub.*(2), now no longer runs into the Cuvierian duct, but runs lateral thereto, to link with a downgrowth of the primary subclavian as described by C. G. SABIN. The old connection with the ductus can still be seen in this embryo, although in fig. 14, Plate 7, a reconstruction of an embryo at approximately the same stage, it can no longer be found.* There can be no doubt that the vein of MACKAY and the root of the secondary subclavian belong to the same capillary system, and indeed, since

---

* The anterior connection of this vessel, though originally at the level of the hyoid arch, appears to retreat somewhat caudally so as to be given off anteriorly from the base of the third aortic arch.

at the five and a half day stage this had already attained definitive form, may be spoken of as one and the same vessel.

The thesis which this section is intended to illustrate is that intimately bound up with the backward migration of the aortic arches are the following features in the development of the vascular system : the establishment of the secondary external carotid, the formation of the secondary subclavian, and the development of the vertebral artery. The secondary external carotid has been dealt with above ; it was concluded that the ventral aorta, unable to elongate at the same rate as the corresponding section of dorsal aorta, breaks in the middle, and its distal half acquires a new connection with the dorsal aorta. The formation of the secondary subclavian has been correlated with the backward migration of the arches by C. G. SABIN. He points out that it is only towards the eighth day of incubation when the arches are reaching their final position and the distance between the base of the third aortic arch and the wing has shortened considerably that the secondary subclavian functionally supersedes the primary vessel.

The development of the vertebral artery is so intimately bound up with the backward migration of the aortic arches that these two phenomena are best described together. In fig. 5 a drawing of a transparency of an embryo at the four day stage, the nervous system, somites, and vascular system are still seen in their undisturbed relations with each other. The first intersomitic artery which can be seen is that of the second interspace which, assuming the visceral clefts to occupy an intersegmental, and the aortic arches a segmental position, lies between the fifth and sixth aortic arches. The same relations hold in the four and a half day embryo of fig. 7 where the backward migration of the arches is being initiated by an arching over of the dorsal aorta just behind the aortic arches. At the five and a half day stage, reconstructed in fig. 8, Plate 4, the third aortic arch is now opposite the first spinal ganglion, having migrated caudally through six segments. At the six and a half day stage, fig. 14, Plate 7, the third aortic arch is opposite the sixth spinal ganglion, and subsequent to the seven and a half day stage is found opposite the fifteenth, indicating a total backward migration through twenty segments.

In text fig. 1 the distance in millimetres between the first twelve spinal ganglia has been plotted against days of incubation for a number of embryos between stages of from three to nine days. It will be seen that the rate of elongation between these two points is much less between the stages of four and a half and seven and a half days. The period between these two stages is precisely that in which the backward migration of the aortic arches takes place. When this process is complete, the anterior region of the body then grows as a whole, the aortic arches maintaining their position relative to the spinal cord.

The results which have emerged from the present investigation of the vertebral artery of the chick will now be described, and will later be compared with those of previous workers. In the five and a half day stage, the arteries and veins of which are shown in figs. 8 and 9, Plates 4 and 5, respectively, and in which the aortic arches have now migrated back through six segments, the three intersomitic arteries in

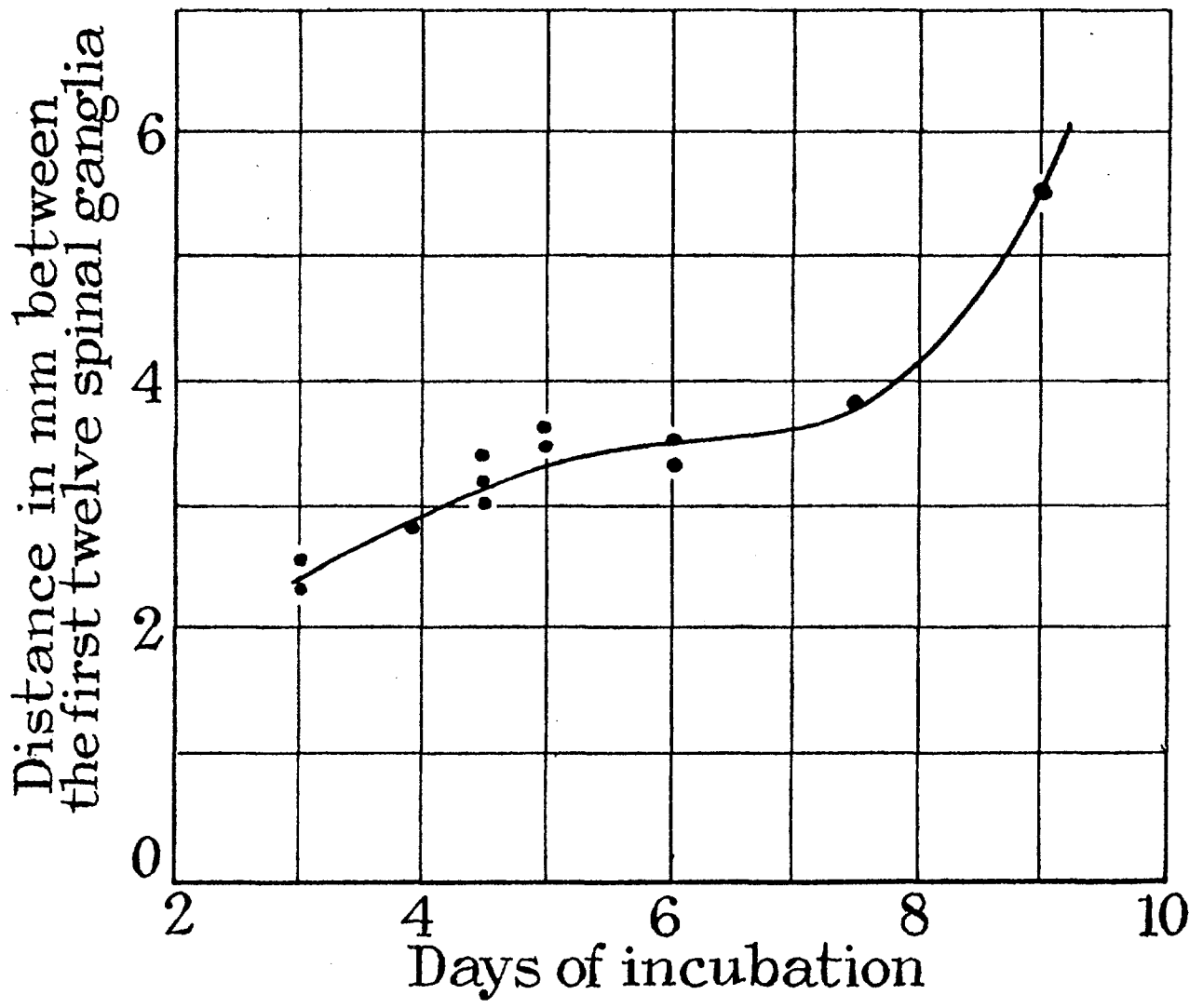

TEXT FIG. 1—Distance in millimetres between the first twelve spinal ganglia plotted against days of incubation, showing the arrest in growth of this region which takes place between the stages of four and a half and seven and a half days, coinciding with the period during which the backward migration of the aortic arches is taking place.

front of the first spinal ganglion, namely, those of the fourth, fifth, and sixth interspaces, have joined together to run into the lateral dorsal aorta at the level of the third aortic arch, *com.c.a.*, fig. 8. This connection is called by FLEMING (1926) the " Arteria cervicalis communis." This keeps the dorsal aorta in communication not only with the three intersomitic arteries in front of the first cervical ganglion, but also with a newly arisen longitudinal capillary plexus along the path of the primary sympathetic chain, *p.sy.pl.*, fig. 8, which lies immediately ventral thereto. This longitudinal plexus is lateral to the intersomitic arteries, and medial to the intersomitic veins, and is shown in fig. 10, at the level indicated in the reconstructions. The effects of the caudal migration of the arches on the intersomitic arteries and veins themselves must now be described. The first three intersomitic arteries found at this stage have already been mentioned ; I was unable to trace any corresponding intersomitic veins. Of the intersomitic arteries behind this level, those as far back as the twelfth interspace—that is, between the sixth and seventh cervical ganglia—have severed their proximal connections with the dorsal aorta. Those behind still run directly at right angles between dorsal aorta and intersomitic space. The intersomitic veins do not yet sever their connection with the cardinals, distally retaining their course at right angles to the latter, but proximal to the primary sympathetic anastomosis turn sharply caudally to enter the cardinals at their original sites, now shifted caudally with the heart and the arterial arches.

Considerable light is shed on the precise way in which caudal migration is accomplished by observation of the form which the intersomitic vessels assume at each stage. Comparing the position of the duct of Cuvier at the four and a half day stage of fig. 7 with that of the five and a half of fig. 9 we see that in the former it is approximately opposite the fifth, and in the latter the seventh cervical ganglion. Yet at the five and a half day stage considerable distortion of these intersomitic veins which run into the anterior cardinal has occurred. This must mean that the region of the anterior cardinal which is elongating originally lay in front of the level of the cervical ganglia. Applying such criteria to the arterial system, the fact that at the five and a half day stage those intersomitic arteries behind the twelfth interspace are as yet undisturbed must mean that the particular section of dorsal aorta between this level and the aortic arches must be contracting in length, leaving that caudal to this level still in its original condition. At the seven and a half day stage reconstructed in fig. 16, Plate 9, the most anterior intersomitic artery as yet undisturbed is that of the eighteenth intersomitic space.

Concomitant with this shortening of the dorsal aorta behind the aortic arches, there must take place a lengthening in front. We can decide whereabouts this elongation principally takes place. The dorsal carotid at the level of the glossopharyngeal and in front remains entirely undisturbed, as is shown by the relationship of this nerve to the secondary external carotid root. Elongation must therefore take place behind this level, one especially intense zone of elongation being that between the Arteria cervicalis communis and the third arch, which at the five and a half day stage appear to lie practically at the same horizontal level.

The primary sympathetic cord between the stages of four and eight day incubation is resolved into the sympathetic nervous system of the body cavity, and as a longitudinal trunk is succeeded by the secondary sympathetic cord, which lies more dorsally than the primary cord and just median to the ventral roots of the spinal nerves. This first appears at the six day stage. By the six and a half day stage it also has acquired an investing capillary plexus, *sec.sy.pl.*, fig. 14, Plate 7, out of which ultimately will be constituted the vertebral vein lateral to the cord, and the vertebral artery medial thereto, all three of which will run in the vertebra-arterial canal of the cervical vertebræ.

At the six and a half day stage of fig. 14 the secondary sympathetic plexus co-exists with the primary plexus, now in process of degeneration. I have been able to trace the intersomitic veins of the eighth to seventeenth interspaces in this embryo, although the corresponding arteries, with the exception of those three in front of the first cervical ganglion, are difficult to trace as definitive vessels, and are represented by dorsal prolongations of the secondary sympathetic plexus in front of the cervical ganglia.

By the seven and a half day stage of fig. 16 there is now no trace of the left fourth aortic arch, which was in process of disappearance in the six and a half day embryo, having lost its ventral connection with the truncus, and being greatly reduced in calibre. The carotid arch now stands in its final position opposite the fifteenth cervical ganglion. No vestiges of the primary sympathetic plexus are to be seen, and the root of the Arteria cervicalis communis, being now opposite the eighteenth interspace, has joined with the persistent intersomitic artery of this interspace, which connects with the secondary sympathetic plexus, now on its medial side acquiring definition as the vertebral artery. Thus the distal part of the vertebral root is derived from the same position as the primary subclavian artery. Behind the eighteenth interspace, several intersomitic arteries still retain their proximal connections with the dorsal aorta, while running distally into the vertebral artery. They are, however, inclined backwards at a considerable angle, indicating that in this region also the dorsal aorta has shifted caudally, though not to such an extent that these intersomitic arteries become severed. The same conditions are met with in the nine day stage, reconstructed in fig. 20, Plate 12, and in all subsequent stages.

The vertebral artery of the adult has one other connection with the arterial system elsewhere, namely, an anterior one. The occipital artery, given off from the external carotid very near its junction with the internal carotid, runs upwards and backwards giving off superficial branches to the neck musculature, *occ.a.l.*, fig. 23, Plate 9, and a deeper branch which runs between the occipital arch and the atlas to form an anterior prolongation of the vertebral artery, *occ.a.v.*, fig. 23. The root of the occipital artery can be recognized at the six and a half day stage, *occ.a.*, fig. 26, Plate 15, as a single capillary channel running upwards and backwards medial to the vagus. In the seven and a half day stage of fig. 16 it connects not with the vertebral artery, but with the vein which will form the root of the vertebra vein, and whose development from lateral offshoots of intersomitic veins is described below. By the nine day stage, however, the occipital artery connects with the vertebral artery, and this lateral occipital vein with the vertebral vein.

TWINING (1906), in his account of the development of the secondary external carotid in birds, does not deal with the development of the vertebral artery in his text, but gives a figure of a six and a half day embryo (his fig. 3*b*) showing the developing vertebral artery connected with the dorsal aorta through an Arteria cervicalis communis, and through the primary subclavian. His figures of stages subsequent to that of six and a half days would imply that the root of the Arteria cervicalis communis became the root of the vertebral which in the adult springs from the common carotid.

KRASSNIG (1913), in his paper on the vertebral artery of mammals and birds, describes the adult arrangement of the vertebral artery in a number of birds, including Gallus, and gives an account of its development in the latter. He commences with the six day stage in which the vertebral anastomosis has taken place, and is here connected with the dorsal aorta by means of the primary subclavian artery. He, however, in his diagram of a ten day embryo (his fig. 14) draws the connection between the vertebral artery and what we regard as the artery of the eighteenth interspace entirely as in his six and a half day stage. He does not describe how the connection with the lateral dorsal aorta anterior to the aortic arches is established, and among the points in which he finds his results at variance with those of TWINING mentions the following : " bildet TWINING bei der Darstellung der Kopfarterien eines 7½ Tage alten Hühner-Embryos bereits die bleibende Vertebraliswurzel als fertig gebildet ab, während ich bei einem gleichalterigen

Embryo wohl die Arterie, die später zur bleibenden Vertebraliswurzel wird, nicht aber ihre Verbindung mit der A. vertebralis selbst ausgebildet finde."

FLEMING studies the development of the vertebral, subclavian, and external carotid arteries in the ostrich, and compares it in these respects with the chick. His description of the development of the vertebral artery in the ostrich may be summarized as follows. The first stage is the dilation of the " first spinal artery," which from FLEMING's figures appears to correspond with the artery of the fourth interspace in the chick. Next, a sinus-like enlargement of the upper end of each succeeding intersomitic artery takes place, followed by longitudinal anastomosis appearing antero-posteriorly. FLEMING says " . . . sinus formation precedes anastomosis ; we find no adequate explanation of this in the mechanics of circulation. It may be noted, however, that these dilatations occur between somites and at the level of the secondary sympathetic chain." The first spinal artery retains its connection with the lateral dorsal aorta, which connection is carried further and further backwards, so that the course of the first spinal artery forwards from its proximal connection is parallel with and dorsal to the dorsal aorta until its own morphological level is reached, when it turns sharply upwards. Just caudal to this point it acquires a new connection with the dorsal carotid, which becomes the root of the vertebral artery.

In the chick, according to FLEMING, the development of the vertebral artery may be looked on as an abbreviation of the course taken in the development of this artery in the ostrich. Whereas in the latter all the intersomitic arteries maintain both proximal and distal connections, up to the stage when the former lie at a level about ten segments behind the latter, in the chick the proximal connections of the intersomitic arteries are lost at a much earlier stage. The formation of the Arteria cervicalis communis is also looked on as an instance of abbreviated development.

FLEMING states that the vertebral artery at the eight day stage has the connection with the occipital vessels which he finds first appearing at six days, as well as two connections with the dorsal carotid, one at the level of the eighth spinal nerve, and the other at the level of the sixteenth segmental artery. He says " that the first of these two persists in the adult may be inferred from TWINING's figures. The fate of the third is unknown to the writer." Close inspection of the figures in TWINING's paper shows, however, only one connection between the dorsal carotid and the vertebral artery, which according to my results arises in two parts, one proximal, the root of the old Arteria cervicalis communis, and the other distal, derived from the artery of the eighteenth interspace, the " sixteenth segmental artery " of FLEMING.

TWINING, therefore, has traced the development of the proximal section of the vertebral root, KRASSNIG that of the distal section.

The important point which emerges from the results of the present study is the intimate connection which exists between the primary and secondary sympathetic cords, and the development of the vertebral artery. FLEMING indeed does mention that the anastomosis which gives rise to the vertebral artery does arise at the level of the secondary sympathetic chain, but his work was undertaken on uninjected material in which one could hardly expect to see a vascular plexus surrounding each sympathetic cord. I think it probable that in the reconstruction of the 16 mm ostrich embryo, shown in FLEMING's fig. 4, the longitudinally coursing part of the first spinal artery together with the mass of intersomitic arteries behind at the same horizontal level represent part of a plexus surrounding the primary sympathetic chain. Furthermore, I feel convinced that the appearance of sinus formation, followed by longitudinal anastomosis at the level of the future vertebral artery, described by both KRASSNIG and FLEMING, which the latter found so difficult to explain, is an artefact, and that the truer picture is that of a longitudinal capillary plexus surrounding the secondary sympathetic chain, and developed soon after the first appearance of the latter.

III—THE VEINS

Account of Previous Work on the Development of the Head Veins

The best account of the development of the head veins of the chick up to the twenty-nine somite stage is that of SABIN, which has been summarized above. It will be remembered that her account leaves off at the stage when the primary head vein has been established, and consists of three separate portions, of which the anterior lies superficial to the plexus of the fore- and mid-brain from which it has originated, and which receives the veins draining the maxillary region. The portion anterior to the maxillary veins, which latter appear in later stages to be the direct anterior continuation of the main head vein, is then known as the anterior cerebral vein. The anterior portion of the primary head vein at the twenty-nine somite stage communicates medial to the trigeminal ganglion with the middle portion, which lies lateral to the facial ganglion, and ventro-lateral to the otocyst, and arises as an anastomosis between the mandibular aortic arch and the anterior cardinal vein into which it runs, and which forms the third section of the primary head vein. Its chief function at this time is to connect the transverse vein of the first interspace with the duct of Cuvier. The transverse vein of the first interspace drains a vein which runs ventro-laterally along the hind-brain from the level of the trigeminal ganglion, medial to the otocyst and the nerve ganglia. This is usually known as the vena capitis medialis, and it is in process of being superseded at this stage by SABIN's "primary head vein," the middle section of which, together with a portion yet to arise behind the transverse vein of the first interspace, and which will be lateral to the glossopharyngeal and vagus, is known as the vena capitis lateralis. The third section of the primary head vein at the twenty-nine somite stage, behind the transverse vein of the first interspace, is morphologically medial to the roots of the glossopharyngeal and vagus, which soon will assume recognizable form.

This account of the head veins in the chick can be continued from that of VAN GELDEREN (1924), who, as part of his work on the comparative embryology of the encephalic veins of vertebrates, studied those of Gallus. His account is, however,

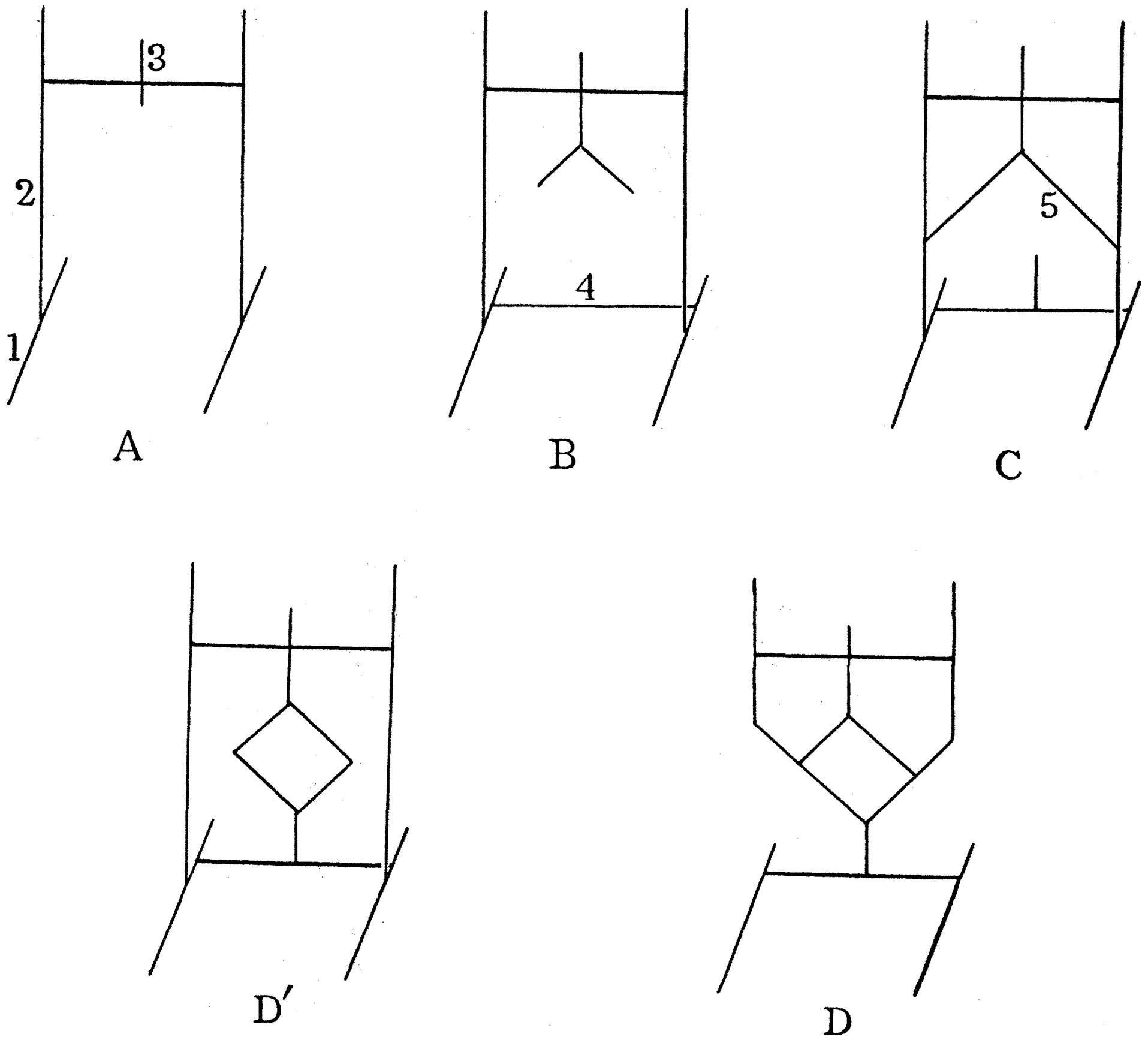

TEXT FIG. 2—VAN GELDEREN's schema illustrating the changes which, according to that author, take place in the occipital veins of the chick towards the end of the incubation period. (A) represents the occipital veins of an embryo of 11 mm head length ; (B) those of a second embryo of the same head length ; (C) of an embryo of 15 mm head length ; (D) of an embryo of 17 mm head length ; and (D′) of an embryo of 20 mm head length.

1. Secondary Stammvene. 2. External occipital vein. 3. Mid-dorsal sinus. 4. Cross-anastomosis between secondary Stammvenen. 5. Occipital vein.

not wholly complete, and in some ways inaccurate. A description of the present work on the subject will follow later.

At four days, a vein lateral to the glossopharyngeal and vagus replaces the third section of SABIN's primary head vein. Into this runs the posterior cerebral vein. Next appears the middle cerebral vein, which enters the main head vein behind the trigeminal ganglion. Anterior and middle cerebral veins send branches to the dorsal region of the brain, which in the mid-dorsal line are gradually resolved into a longitudinal mid-dorsal sinus, which will ultimately form the main drainage channel for the brain.

Early in the ninth day of incubation that section of the head vein between the level of the facial and glossopharyngeal nerves which runs dorsal to the Eustachian tube is short-circuited by a new vessel which runs ventral to the latter. The vessel dorsal to the Eustachian tube VAN GELDEREN calls the " primäre Stammvene," and the new channel ventral thereto the " secundäre Stammvene." In embryos of from nine to ten days of incubation the primary Stammvene, according to VAN GELDEREN, begins to disappear, its posterior section being retained, however, to join with a transverse vessel, the V. anastomotica posterior which runs across the mid-dorsal sinus at a level just caudal to that of the developing cerebellum. The connection of the V. anastomotica posterior with the hind section of the primary Stammvene is called by VAN GELDEREN the V. emissaria occipitalis and leaves the cranium through a foramen in its side wall to enter the primary Stammvene at a point behind where the posterior cerebral vein entered, which has by now disappeared. Soon the basal sections of the anterior and middle cerebral veins disappear also.

A cross-connection develops between right and left secondary Stammvenen, and the vessels of the right side become larger in diameter than those of the left. Soon a new system of occipital veins is developed, the mid-dorsal sinus growing backwards bifurcates round the hind-brain at a level immediately caudal to that of the hypoglossal, and ultimately reunites below the hind-brain to form a median vessel which runs into the cross-anastomosis between the secondary Stammvenen. These veins running round the hind-brain at this level VAN GELDEREN calls the Vv. occipitales. According to him, the V. occipitalis of each side passes through an intermediate stage of development in which it at first runs into the veins joining the V. anastomotica posterior with the posterior section of the primary Stammvene, namely, the V. emissaria occipitalis. Finally, however, according to VAN GELDEREN, the proximal section of the V. emissaria occipitalis disappears, and with it the last remnant of the primary Stammvene. The V. anastomotica posterior discharges through the distal section of the V. emissaria occipitalis of each side into the V. occipitalis. Thus in VAN GELDEREN'S account, the V. occipitalis communicates with the V. emissaria occipitalis first when the latter is complete, then loses this connection on the formation of the median ventral vessel discharging into the anastomosis between the secondary Stammvenen, finally to regain this connection when the aforementioned median vessel becomes the only drainage channel for the head veins, consequent on the atrophy of the proximal section of the Vv. emissaria occipitales. VAN GELDEREN'S schema which illustrates these changes is here reproduced as text fig. 2. One final change must be noticed, namely, that the distal sections of the anterior and middle cerebral veins become connected by a lateral longitudinal anastomosis, the V. anastomotica anterior.

NEUGEBAUR studied the adult distribution of the head sinuses in the turkey (NEUGEBAUR, 1844). His work is summarized by GADOW and SELENKA (1891) in the anatomical section on birds in BRONN'S " Tierreich." NEUGEBAUR distinguishes nine head sinuses in birds, of which all but two can be recognized from VAN GELDEREN'S account. One of these is NEUGEBAUR'S Annulus venosus basilaris. This is a sinus within the sella turcica, surrounding the chiasma and hypophysis, into which flow the anterior and middle cerebral veins ventrally (NEUGEBAUR'S tempero-sphenoideus and petrosphenoideus sinuses respectively), which in the adult no longer communicate with either primary or secondary Stammvenen. The second of NEUGEBAUR's nine sinuses which does not appear in VAN GELDEREN's account is the Sinus foveæ hemispherii cerebelli, which lies in the floor of the inner ear cavity and runs into what NEUGEBAUR terms the "Vena auris interna." VAN GELDEREN says, in comparing his results with those of NEUGEBAUR, "Nur seine V. auris interna kann ich nicht als Hirnschädelvene anerkennen." GADOW and SELENKA quote RATKE's (1838) work on the development of the head veins of the chick. RATKE obviously must have seen the development of both primary and secondary Stammvenen. NEUGEBAUR, in comparing his work on the adult distribution of the head veins with the embryological work of RATKE, concludes that the V. auris interna is none other than the persistent posterior section of the primary Stammvene. This conclusion I have been able to confirm. Moreover, I further disagree with VAN GELDEREN with regard to the final form assumed by the occipital vessels. His Vv. emissaria occipitales I find to be still complete at the stage of hatching.

The ventro-lateral longitudinal veins

Under this heading may be included those systems of veins to which the names Vv. capitis medialis and lateralis, the primary head vein of SABIN and the primary and secondary Stammvenen of VAN GELDEREN. These names overlap to a considerable extent, and it is necessary to define accurately the senses in which they are to be used. Vena capitis medialis refers to a head vein at any level which is medial to the nerve ganglia. In the neighbourhood of the trigeminal, inasmuch as the permanent head vein is medial to the maxillo-mandibular branch, it is here spoken of as part of this vein. The vena capitis lateralis runs lateral to the nerve ganglia, and its development from behind the trigeminal to the level of the transverse vein of the first interspace is described by SABIN. This section of it is her "middle section of the primary head vein." Of the rest of her primary head vein, the anterior section is later known as the anterior cerebral vein plus the section of the vena capitis medialis at the level of the trigeminal, while the posterior section is still vena capitis medialis as well. VAN GELDEREN's primary Stammvene is vena capitis medialis in the neighbourhood of the trigeminal, and vena capitis lateralis caudalwards to the level of the vagus. The secondary Stammvene is a new formation ventral to this, maintaining the same relationships to the nerves except that it is medial to the glossopharyngeal beyond its ganglion. It seems better to retain these names, and to use them in strict senses rather than to add to an already overburdened nomenclature. When no precise morphological sense is intended, the term "head vein" will be used.

Fig. 2, Plate 2, is a reconstruction of the head veins of an embryo of thirty somites, and is to be compared with fig. 1, Plate 1, reproduced from Miss SABIN's figure of the twenty-nine somite embryo. My thirty somite stage is slightly more advanced in that the middle section of SABIN's primary head vein is considerably larger in diameter. In front of the auditory vesicle is a vertical branch of the medial head vein, and behind is a vertical branch of the lateral vessel, and these two branches meet over the auditory vesicle. In fig. 3, Plate 2, a drawing of a transparency of a thirty-two somite embryo, no medial head vein can be recognized at all, and the vertical branch in front of the auditory vesicle now drains into the lateral head vein. This will become the middle cerebral vein, and the branch behind the auditory vesicle the posterior cerebral vein.

The morphological level of the posterior cerebral vein is that of the first interspace—that is, between the glossopharyngeal and vagus. This follows from an inspection in fig. 2, where the head vein opposite the glossopharyngeal is seen to be the lateral vessel, while that section opposite the vagus is still medial thereto. Fig. 6, Plate 3, a reconstruction of the head vein of an embryo of four and a half days, shows the first appearance of the lateral head vein at the level of the vagus, *l.h.v.X.* It is at this stage a slender capillary bridging the nerve. Behind the level of the vagus the head vein has acquired a branch which runs parallel with it for some distance caudally, *ext.occ.v.* This is the future root of the external occipital vein, and is to be seen in KASTSCHENKE's fig. 10, which LILLIE, in his " Development of the Chick " reproduces as fig. 102. A secondary connection behind the vagus between the posterior cerebral and the external occipital root obscures the pre-vagal relationships of the former, and distorts the transverse vein of the first interspace into a post-vagal position. Its true relations are, however, clearly seen in earlier stages.

Some account of the intersomitic veins has already been given above, in dealing with the backward migration of the vascular system. In fig. 6 we can see six intersomitic veins in front of the first spinal ganglion, which is one for each interspace, including the first. Already those intersomitic veins furthest forward run not at right angles to the main axis, but are canted backwards, indicating that backward migration is already taking place. In the five and a half day stage of fig. 9, Plate 5, no intersomitic vein further forwards than that of the seventh interspace—that is, between the first and second spinal ganglia—can be traced. The disappearance of those anterior to this level is probably due to two causes, one the backward migration, and, secondly, the replacement in the neighbourhood of the vagus of the medial head vein, into which the anterior intersomitic veins flowed, by the vena capitis lateralis. Those intersomitic veins behind the sixth interspace still persist, although in their proximal regions are strongly inclined backwards. Those of the seventh, eighth, and ninth interspaces have run together to form a common trunk, which has acquired a superficial branch, connected with a system of superficial capillaries in the neck region which arises at this time. In the six and a half day embryo whose veins are reconstructed in fig. 11, Plate 6, this superficial branch of the common trunk of these intersomitic veins, *l.b.i.v.*, which no longer present themselves, has taken up the position which it will occupy in later stages as a drainage channel for the vertebral vein. It is best known as the lateral occipital vein. The seven and a half day embryo of fig. 15, Plate 8, is anomalous in this respect in that this vessel is given off in front of the hypoglossal. In the six and a half day embryo of fig. 11 all those intersomitic veins flowing into the anterior cardinal have disappeared, the longitudinal anastomosis of the primary sympathetic chain still persists, however, and communicates with the anterior cardinal near the duct of Cuvier by means of the stumps of some of the intersomitic veins. In this respect, therefore, this embryo is more advanced than that of fig. 14, Plate 7, of the same age, but in which intersomitic veins can still be traced in connection with the longitudinal anastomosis of the primary sympathetic chain. With the development of the vertebral vein from the longitudinal anastomosis of the secondary sympathetic chain we shall deal later.

In the reconstructions of the stages of five and a half, six and a half, and seven and a half days of figs. 9, 11, and 15, Plates 5, 6 and 8, respectively, the dotted circle in the region of the facial nerve represents the upper end of the hyoid visceral pouch. This migrates dorsally, pushing before it the head vein in this region, which arches upwards in conformity with the upward growth of the future Eustachian tube. This, in the opinion of the writer, is an important factor concerned in the replacement of the primary by the secondary Stammvene. The secondary Stammvene can be seen in the six and a half day stage of fig. 11 and in the seven and a half day of fig. 15 as a ventral branch of the primary Stammvene running forwards medial to that section of the glossopharyngeal distal to its ganglion, *sec.St.p.r.* At the eight and a half day stage of fig. 18, Plate 10, this has grown forwards considerably ventral to the Eustachian tube, which by this time has attained a level still more dorsal, to unite with the primary Stammvene at two points, one anterior, just where the maxillary vein, *mx.v.*, joins the primary Stammvene, and the other immediately in front of the tympanic cavity. This latter connection I have called the " pretympanic connective," *p.t.c.*(1).

In the embryo of eight and a half days of incubation of fig. 18 the secondary Stammvenen have already acquired their cross-anastomosis with each other. This cross-anastomosis can be traced back to a plexus of a characteristic type of capillary, which can be seen in the roof of the pharynx at this level in the seven and a half day stage. These capillaries, while being larger than those encountered in earlier stages, retain their early thinness of wall and irregularity of distribution. They are exceedingly characteristic of the development of many of the head veins. It is proposed to use the term " venule " in referring to such enlarged capillaries which give rise to veins in this manner. The cross-anastomosis between the secondary Stammvenen at the eight and a half day stage is readily seen to be composed of but recently fused venules, being very irregular. Venules are growing upwards and backwards from it in the middle line, and these, when the horizontal level of the base of the brain is reached, will bifurcate round the hind-brain, and will meet on each side a similar bifurcation of the mid-dorsal longitudinal vessel, thus forming a venous ring round the hind-brain at a level immediately caudal to that of the hypoglossal. This ring with its dorsal and ventral connections forms the Vv. occipitales of VAN GELDEREN, the Sinus foraminis occipitalis of NEUGEBAUR. I have traced the development of the ventral connection with the cross-anastomosis between the secondary Stammvenen in three drawings of transverse sections, figs. 19, 22, and

25, Plates 11, 13 and 14, which refer to embryos of eight and a half days, twelve days, and the hatching stage respectively, and are at the levels indicated in the corresponding reconstructions. It will be seen how the cluster of venules develops into a pair of definitive veins on either side of the middle line.

We must now trace the development of the Vv. emissaria occipitales of VAN GELDEREN, which can be referred to more simply as the external occipital veins. VAN GELDEREN states that they arise on each side at a level more caudal than that of the posterior cerebral, which is in accordance with the account which has been given above. Both are seen together in stages between four and a half and six and a half days, figs. 6, 9, and 11, the posterior cerebral running upwards through the cartilage of the posterior wall of the auditory capsule, the external occipital root backwards, ventral to the auditory capsule, ending outside the cartilage of the occipital arch. At the seven and a half day stage, the posterior cerebral vein has disappeared, possibly correlated with the increase in density of the cartilage of the auditory capsule. Not until the eight and a half day stage does the external occipital root establish connection with a bunch of venules growing laterally and downwards from the mid-dorsal sinus, *ext.occ.v.*, fig. 18. The point of junction is marked by the point where the external occipital runs through its foramen in the side wall of the cranium ; the V. anastomotica posterior of VAN GELDEREN is inside the cranium, the root of the external occipital is outside, as described above. At the twelve day stage, occipital, *occ.v.*, fig. 21, Plate 11, and external occipital veins acquire a connection with each other, but further than this, as far as I am able to make out, no change takes place. In the chick at hatching, the basal portion of the external occipital vein is as well developed as in earlier stages. In this, I differ from VAN GELDEREN, but agree with NEUGEBAUR, as summarized in BRONN.

I again agree with NEUGEBAUR, but disagree with VAN GELDEREN respecting the fate of the posterior section of the primary head vein, the V. auris interna. I find that whereas at the eight and a half day stage, both primary and secondary Stammvenen are complete, with the pretympanic connective developed, fig. 18 ; at the twelve day stage, that section of the primary Stammvene opposite the pretympanic connective has dropped out, together with the dorsal end of the latter whose ventral end is now left as a vein running upwards from the secondary Stammvene immediately in front of the tympanic cavity, fig. 21. The section of the primary Stammvene anterior to this point, which appears as a dorsal prolongation of the maxillary vein above the secondary Stammvene now runs into the temporal rete. The relations of the latter with the venous system are described below, when the region of the head vein anterior to the trigeminal is discussed.

That section of the primary Stammvene which is retained acquires two new connections, which in NEUGEBAUR'S nomenclature are the Sinus foveæ hemispherii cerebelli and the Vena carotis. The former, which perhaps can most simply be referred to as the floccular vein, *f.v.*, fig. 24, Plate 10, is intimately related in the region of the flocculus with the cerebellar artery. It parts company with it, however, to run laterally downwards in the wall of the auditory capsule, and then across the floor of the latter to run into the V. auris interna. I have not been able to trace it in any earlier stage ; at twelve days the flocculus is not yet developed ; the floccular vein probably develops concomitantly therewith.

The Vena carotis runs in the carotid canal in the basitemporal with the internal carotid, *c.v.*, fig. 24. It consists of a strand of venules, a continuation of those of the sella turcica which form the Annulus venosis basilaris of NEUGEBAUR, the development of which is traced below. By the twelve day stage these venules are spreading backwards along the carotid, and in the chick at hatching have joined with the posterior section of the primary Stammvene, just before the latter divides into the external occipital vein and the V. auris interna, the latter of which is really its continuation.

The blood vessels of this region are remarkable for furnishing a number of examples of an identity of path between arteries, nerves, and veins. Thus the V. auris interna runs through the cranio-quadrate passage with the stapedial artery accompanied by branches of the facial nerve, the descending hyomandibular branch behind the facial root, and the chorda tympani in front. The course of the stapedial forwards, in its relations to surrounding structures which is described above, applies equally well to the V. auris interna for as far forward as this vessel persists.

To the larynx run all together the laryngeal vein, *l.v.*, fig. 24, the superior laryngeal branch of the external carotid, *s.l.a.*, fig. 23, the laryngeal branch of the glossopharyngeal, and for some distance, the main trunk of the hypoglossal. This laryngeal vein can be traced from the six and a half day stage as a definitive vessel, given off ventrally from the main head vein at a level slightly caudal to that of the secondary Stammvene, and always related in this way to these two nerves.

Associated with the pretympanic connective between primary and secondary Stammvenen is the external facial vein, *ext.f.v.*, fig. 24, which is related with arterial vessels in an interesting manner. The pretympanic connective itself runs upwards immediately in front of the tympanic cavity to end blindly when the primary Stammvene in this region has gone, and is accompanied by a branch of the external facial artery, *ext.f.a.*, fig. 23, given off dorsally as this arches over the quadrate. The external facial artery then runs in front of the latter from its medial to its lateral surface, from whence it proceeds forwards to enjoy an extensive superficial distribution. It is accompanied proximally by that section of the external facial vein which is anterior to the quadrate and which has a similar distribution. The remainder of the external facial vein lies behind the quadrate, and runs dorsally to be accompanied by the auricular artery, *au.a.*, fig. 31, Plate 16. The external facial vein can first be traced from the eight and a half day stage, at which time the pretympanic connective first appears. It is remarkable in later stages for furnishing a branch, *inf.alv.v.*, fig. 24, which accompanies the mandibular branch of the trigeminal and the inferior alveolar branch of the stapedial artery into the inferior alveolar canal. This vein I have not been able to trace beyond a stage earlier than that of eighteen days of incubation.

The inferior alveolar branch of the stapedial and the maxillo-mandibular branch of the trigeminal are accompanied proximally from the rete by the section of primary Stammvene in front of the level of the pretympanic connective which persists, and which in the adult runs into the temporal rete, *p.St.a.*(2), fig. 24. It appears to be continued ventral to the main head vein, which posterior to this point is secondary Stammvene, by the maxillary vein, *mx.v.*, fig. 24. This is accompanied by the spheno-maxillary artery, *sph.-m.a.*, fig. 23, for a considerable distance, and distally by the maxillary branch of the trigeminal. A branch of the maxillary vein, *pal.v.*, fig. 24, accompanies the palatine branch of the facial, which also has a branch of the internal carotid to accompany it. The palatine vein branches into two when the palatine branch gives off its ventral branch.

We must now proceed with the description of the main head vein anterior to the level of the trigeminal, the relations of which with the temporal rete and the sinus of the sella turcica reveal further instances of correspondence in path of arteries and veins.

The whole head vein anterior to the trigeminal is really the primitive maxillary vein of Sabin, which at the twenty-nine somite stage is connected with the marginal vein of the optic cup and, more anteriorly, with the fore-brain plexus in the olfactory region. Sabin says, with regard to the primitive maxillary veins, "In the chick of the fourth and fifth days of incubation this group of veins clearly drains the entire maxilla and receives branches from the most anterior part of the cerebrum and a group of inferior ophthalmic veins, of which one of the most important runs in the optic stalk. Therefore I have preferred to limit the name primitive ophthalmic veins to the branches of the primitive maxillary vein instead of calling the entire trunk the ophthalmic veins." As, however, by the six and a half day stage this vein has itself acquired a branch which drains the maxilla, I shall refer to the main trunk as the anterior continuation of the head vein, which, on the straightening of the cranial flexure, it directly appears to be.

The main tributary of the anterior continuation of the head vein is the anterior cerebral vein, *V.cap.p.*1., fig. 1, the first section of Sabin's primary head vein, which originates as a superficial plexus given off from the deep primary plexus of the fore- and mid-brain. It runs into the head vein anterior to the trigeminal root, and is lateral to the ophthalmic branch of the trigeminal. The superficial plexus extends further and further towards the mid-dorsal line of the fore-brain, being preceded by the deep plexus which gives off superficial capillaries which are incorporated with the branches of the anterior cerebral vein. Once the mid-dorsal line is reached by the superficial plexus, a longitudinal channel is established along this path, which for a considerable time takes the form of an aggregation of venules.

Meanwhile, the more proximal region of the anterior cerebral vein becomes involved with the capillary plexus extending forwards over the orbit from the now fused superficial plexuses of the mandibular and hyoid arches. This occurs early in the sixth day of incubation. Above, in the section devoted to the stapedial artery, the derivation of the supraorbital branch of the stapedial from this plexus is described. It also gives rise to a vein running together with this artery, and which proximally forms a forwardly directed branch of the anterior cerebral vein, *oph.a.c.v.*, fig. 11. This morphologically lies outside the developing cranial wall, while the branches of the anterior cerebral vein, which are forming the mid-dorsal sinus, lie inside.

This supraorbital vein extends further and further forwards as a definitive vessel, and finally joins with the head vein in the olfactory region, *oph.a.c.v.*(2), fig. 18. By this time the proximal part of the anterior cerebral vein has atrophied, leaving only the intracranial section, which is beyond the junction with the supraorbital vein. This latter, then, is now represented only by its anterior section, draining into the head vein in the olfactory region. Fig. 18, the reconstruction of the eight and a half day embryo, represents this stage. The stump of the anterior cerebral still remains. In this embryo, there is an exceptional connection between the intracranial part of the anterior cerebral vein and the head vein between the olfactory region and the old anterior cerebral root, which I have not observed at any other stage. The anterior section of the supraorbital vein persists in the chick at hatching as a drainage channel for the orbit, associated with which in earlier stages are other veins draining the orbit, but which have disappeared at the hatching stage, fig. 24. By this stage, a paired connection between the anterior end of the mid-dorsal sinus and the head vein anterior to the cerebral hemispheres has been acquired.

In the olfactory region, the head vein has drained a plexus of capillaries springing from the fore-brain plexus from the twenty-nine somite stage onwards. This has differentiated into arteries lateral and medial to the olfactory sac respectively by the four and a half day stage. The connection of the head vein with this system is retained when the olfactory nerves and ethmoidal arteries elongate at about the stage of seven days of incubation, concomitant with the increase in depth of the interorbital septum. The prolongation of the head vein down the olfactory nerves we may term the ethmoidal vein, *eth.v.*, fig. 24.

The development of that vein, which SABIN found to run in the optic stalk, must now be traced. This is the blood vessel of the choroid fissure, which in forms other than birds establishes connection with the ophthalmic branch of the internal carotid, to form the Arteria centralis retinæ. It can be traced from the four day stage onwards, *v.ch.f.*, fig. 5 ; it is developed from the marginal vein of the optic cup, one capillary of which enters the choroid fissure. It lies at right angles to the ophthalmic arteries of the internal carotid and middle cerebral, which are also differentiated out of the marginal vein of the optic cup, as described above.

When the sclerotic has chondrified, and the pecten has been formed along the line of the choroid fissure, the vein of the choroid fissure is given off from the head vein to take up a position opposite that of the pecten, and runs downwards outside the sclerotic for some distance, finally piercing the latter, from which point it continues downwards immediately adjacent to the medial surface of the optic nerve, which runs along the base of the pecten.

The vein of the choroid fissure is given off from the head vein at a level anterior to that of the maxillary vein, but at the same level at which a vein accompanying the distal section of the palatine branch of the facial is given off in stages earlier than that of twelve days of incubation, *pal.v.*, fig. 18, Plate 10. At this stage and beyond the palatine vein becomes a branch of the maxillary vein, fig. 21, Plate 11. The maxillary vein is accompanied by the spheno-maxillary artery, and the differentiation of these two vessels furnishes an extremely clear instance of the condensation of an artery and a vein from the same system of capillaries. The maxillary veins are at first extremely irregular, they first appear at the stage of six and a half days, *mx.v.*, fig. 11, Plate 6, when a vein is differentiated in the maxilla, parallel to the head vein, and connected to the latter by a series of capillaries extending from the level of the vein of the choroid fissure for some distance caudally. At the eight and a half day stage, this system has differentiated into a branch of the head vein given off behind the level of that of the choroid fissure vein, and branching into two rami in the region of the maxilla.

The account of the head vein anterior to the trigeminal level must be concluded by a description of its connections with the temporal rete, and with the sinus of the sella turcica. Some account was given above of the development of the temporal rete, under the section devoted to the stapedial artery. It was shown how the rete takes origin from a plexus of capillaries surrounding the laterally directed branch of the trigeminal. These enlarge to form venules, which at the stage of twelve days of incubation gain a connection with the main venous system through the descending anterior portion of the primary Stammvene, which has by now lost connection with its posterior portion, which forms the V. auris interna of NEUGEBAUR. Later, a second connection is established between the head vein and the temporal rete, which can be described after the development of the sella turcica sinus has been traced.

Fig. 13, Plate 7, is a drawing of a section through the head of an embryo of six and a half days, at the level of the base of the mid-brain, as indicated in the reconstruction of the same embryo in fig. 11, Plate 6. The general capillary plexus surrounding the brain extends into this region, and is especially dense round the saccus infundibuli, *s.inf.*, fig. 13. Later, capillaries in the sella turcica become venules, as is shown in *s.t.s.*, fig. 22, Plate 13, a section through the head of a twelve day embryo, at the level indicated in fig. 21, Plate 11. Like the venules of the temporal rete at a somewhat earlier stage, these have as yet no connection with the main venous system. However, in front of the point where the anterior cerebral vein entered the head vein, a new side branch develops, *s.t.s.v.*, fig. 21, which soon receives venules which come from the sella turcica and which accompany the internal carotid ophthalmic on its way to join with that of the stapedial. These run dorsal to the optic nerve. At the stage of hatching, the venules of the sella turcica have expanded very largely to fill all that space not occupied by other structures, *s.t.s.*, fig. 25, Plate 14. They have also extended backwards along the path of the internal carotid, within the carotid canal in the basitemporal, to establish connection with the primary Stammvene, as shown in fig. 24, the reconstruction of the veins of the chick at the hatching stage. Thus is formed the Vena carotis of NEUGEBAUR.

The ophthalmic branch of the stapedial issues from the antero-dorsal corner of the temporal rete, to arch over the rectus externus and run downwards to join with that part of the internal carotid ophthalmic lateral to the ciliary ganglion. Along its path grows a venule, which by the twelve day stage has not established connection with the venous system elsewhere, but at the hatching stage has formed a large vein arching over the rectus externus with the ophthalmic branch of the stapedial, and running into the vein joining sella turcica and main head vein, *t.r.v.*, fig. 24, Plate 10.

The mid-dorsal longitudinal vein

The mid-dorsal longitudinal vein arises by the coalescence of superficial plexus in the mid-dorsal line in the form of venules, connected with the anterior and middle cerebral veins. This has been shown previously in the human embryo (MALL, 1904, STREETER, 1918). In the chick, the anterior cerebral vein is responsible for the formation of that section of mid-dorsal sinus opposite the fore-brain and the anterior surface of the optic lobes. The contribution from the middle cerebral extends from the posterior surface of the optic lobes backwards.

In the reconstructions, I have not traced the finer dorsal ramifications of the anterior and middle cerebral veins. Such channels as are shown represent venules, or coalesced venules. In the six and a half day stage of fig. 11, Plate 6, the anterior cerebral of the left side has formed a section of mid-dorsal sinus over the anterior surface of the optic lobe, *mid.d.s.*, in which the right anterior cerebral has no part. The mid-dorsal product of the middle cerebral is more extensive, and in this the middle cerebral veins of both sides participate.

These two sections of mid-dorsal sinus have met over the optic lobes in the eight and a half day stage of fig. 18, Plate 10. Both anterior and middle cerebral veins have lost their original proximal connections with the head vein, although in this embryo the anterior cerebral has an altogether exceptional connection with the head vein in front of its earlier point of origin, the stump of which remains. In the region of the fore-brain the mid-dorsal sinus is assuming its final form. The anterior cerebral veins unite dorsally in a transverse sinus at the level of the paraphysis, which medially on its posterior face runs into the mid-dorsal longtitudinal sinus, and anteriorly receives three veins. One is a median vein which runs directly downwards in front of the paraphysis to the anterior choroid fissure, the other two are paired veins which run forwards medial to the cerebral hemispheres, and by the hatching stage have established connection with the head vein lateral to the olfactory bulbs. With the formation of the adult pineal body, which lies at a level anterior to that of the antecedent structures, the epiphysis and paraphysis, the vein to the anterior choroid plexus takes up a position lateral to the pineal, which in the eighteen day stage, and in the chick at hatching which have been studied lies to the left of the latter.

At a level just behind that of the future cerebellum is another transverse vein connected with the mid-dorsal longitudinal sinus, the V. anastomotica posterior of van Gelderen. It can first be traced at the seven and a half day stage, *ext.occ.v.d.*, fig. 15, Plate 8. In the eight and a half day stage it has joined with the root of the external occipital vein, *ext.occ.v.*, fig. 18, Plate 10. The latter lies outside the cranium, while the V. anastomotica posterior lies inside. Behind this level the mid-dorsal sinus bifurcates round the hind-brain at a level immediately caudal to that of the hypoglossal, to meet a bifurcation growing upwards from the median vessel beneath the brain, which arises from the cross-anastomosis between the secondary Stammvenen. This, as explained above, forms the occipital veins of van Gelderen, the sinus foraminis occipitalis of Neugebaur. This I have found to conform in an interesting manner with the axial skeleton in this region, fig. 24. The main foraminis occipitalis fills up the space between occiput and atlas, but between the atlas and the axis is another sinus which is not completed ventrally, but follows the second cervical nerve outwards from the vertebral column. These two sinuses communicate dorsally, and from this point is continued a mid-dorsal sinus down the vertebral column, immediately internal to the neural arches. Side branches are given off from this longitudinal sinus, which anastomose lateral to the secondary sympathetic chain to form the vertebral vein. The latter always remains in a more or less irregular form, and arises from the secondary sympathetic anastomosis much later than does the vertebral artery on the medial side of the sympathetic cord. Branches are given off from the vertebral vein to run outwards with each nerve root, and in between the first and second cervical ganglia runs the connection with the lateral occipital vein. In figs. 18 and 21 the vertebral vein is represented more or less diagrammatically, being then in an indefinite condition. In the reconstruction of the hatching stage, fig. 24, it was, however, possible to trace its anastomoses with the mid-dorsal spinal sinus in a definitive form. The latter only develops quite late. Venules are first seen extending down the spinal cord mid-dorsally from the occipital region at the stage of twelve days.

Certain venous connections within the cranial cavity described by Neugebaur I have been unable to find. There should, according to him, be a connection between the anterior cerebral and the middle cerebral vein laterally across the dorsal surface of the optic lobe on each side. Moreover, these veins should run ventrally into the sinus of the sella turcica, which should give off anteriorly and posteriorly a median basilar sinus. It is possible to trace these connections in the form of venules at the hatching stage, by which time they have not yet attained the status of definitive vessels. It is not impossible that the formation of definitive vessels from venules may extend beyond the hatching stage.

IV—Discussion

Definitive blood vessels are, in general, preceded by a stage of capillary plexus. An exception to this generalization may be made for the early vessels in the embryo, the dorsal and ventral aortæ, and the aortic arches. Opposition to this view of the antecedence of capillary plexus to definitive vessels has been confined to the school of HOCHSTETTER, whose opinions have been voiced in a concise and polemical way by ELZE (1913). This author's objections to the "Netztheorie" turn on the simplicity of form which the intersomitic vessels at first assume, being in the embryos of Anamniotes simple loops between the main longitudinal arteries and veins. This argument may be met by stating in the first place that since the somites are at first non-vascular areas and lie in very close apposition to each other, there is hardly room for the development of an extensive plexus between them. In the second place, the intersomitic vessels do not in themselves provide good examples of the "Netztheorie," which is in no way invalidated by the admission of exceptions. Many good examples of the antecedence of capillary plexus are known, not a few of which appear in the present work.

Otherwise, we may perhaps assign the date of the general acceptance of the theory from the work of EVANS in 1909, whose conclusions on the subject of the development of the primary subclavian artery have been summarized above.

EVANS summarizes the work of THOMA on the vitelline vessels of the chick. These at first take the form of a uniform meshwork of capillaries. Those which are situated in the direct line of the vitelline veins and of the aorta enjoy a more constant and rapid circulation than do other capillaries of the meshwork. Those more favourably situated channels develop in later stages into the veins and arteries of the yolk sac respectively. The formation of a definitive blood vessel is therefore dependent upon function. THOMA stages his conclusions in the form of three laws, which are as follows :—

1. The increase in size of the lumen of a vessel depends upon the rate of the blood current.
2. The growth in thickness of the vessel wall is dependent upon its tension. The tension of the wall is dependent upon the diameter of the lumen of the vessel, and upon the blood pressure.
3. Increase of the blood pressure in the capillary areas leads to the formation of new capillaries.

The influence of the blood stream upon the developing circulation has been the subject of experimental study upon more than one occasion. ROUX (1879), in a classical paper, concluded that in a fully formed circulation, branches are given off from a main artery in such a manner as to give rise to the least possible fluid friction. Smaller branches are given off at an angle which is nearer ninety degrees than for larger ones, and the cross-section of a branch immediately near the main trunk is oval rather than round. Such configurations correspond exactly with those of columns of fluid flowing out of an opening.

The morphological form assumed by the circulatory system as a whole under experimental conditions was studied by two American observers, whose results are published in the same volume of the same journal, and who between them review the early experimental work on the subject. CLARK (1918) used as experimental material in a series of studies, the circulation in the transparent web of the tail of a tadpole, and studied its development both in normal animals and in those in which the heart had been removed. CLARK concluded that the differentiation of a uniform capillary field into definitive arteries and veins with a residual plexus between them is conditioned by two factors, the first of which is identical with the first law of THOMA, with the exception that for " rate of blood stream " is substituted " amount of blood flow."

CLARK's second factor is the amount of interchange which takes place through the endothelial wall of the vessel. An increase results in the formation of a sprout, a characteristic reaction of endothelium noticed by both CLARK and SABIN (1920). Decrease in the amount of interchange results in the contraction of the lumen.

The second study is that of CHAPMAN (1918), who destroyed the heart of chick embryos at the sixteen somite stage, and watched the further development of the area vasculosa. At this stage, when the circulation is about to begin, the network of the area vasculosa is still a largely uniform plexus, the only differentiation that has taken place being the sinus terminalis. CHAPMAN's work tells us how far differentiation can go on within the area vasculosa when the formative influence of the circulation is absent.

The only vessel which differentiates is the anterior vitelline vein, otherwise the only resemblance between operated and unoperated blastoderms is the rate at which the sinus terminalis breaks up into capillaries. CHAPMAN regards the powers of self-differentiation of the blood vessels as being very limited. No enquiry into the capacity for self-differentiation of the main vessels of the embryo has yet been made. Experiments are, however, in progress on this problem using tissue culture methods. To apply the conceptions of THOMA and others to the problem of intra-embryonic vascular development, we must picture an underlying morphological plan which gradually unfolds as development proceeds, and in conformity with which the vascular system condenses out of a series of capillary plexuses. Unless we can shed some light on the nature of this pre-existing plan, each stage in the development of which presumably conditions the next, and which involves the whole general problem of the nature of the causes underlying development, we are not likely to advance far along this path. One fact we may, however, notice at the outset.

The capillary system of even an early embryo is by no means a uniform one, and is itself conforming to a morphological plan. It is this fact which renders the " Netztheorie " in a rigid form untenable. Certain areas of early embryos have a dense supply of capillaries, while others in certain circumscribed areas remain bare for considerable periods. One of the most fruitful lines of advance in the study of capillary distribution would seem to be the intensive study of such non-vascular areas. The somites until about the six day stage in the chick are non-vascular areas, so is the central nervous system until about four days, so also are layers of definite thickness beneath the limiting epithelia of the body. The last type of non-vascular area we can readily see in injected limb-buds.

It seems permissible as a preliminary hypothesis to attempt to explain the condensation of capillary plexus round an organ which itself for some time remains non-vascular as some form of contact response. We are reminded in this connection of the important part which thigmotropism plays in tissue culture. This type of hypothesis would have the advantage of postulating no specific properties for vascular tissue ; we should expect such contact reactions to be shared by any migrant coherent tissue, such as developing nerves. With regard to the latter, we have the evidence of the work of HAMBURGER on the point.

In his study of the influence of the nervous system of the development of the limbs in Rana fusca (HAMBURGER, 1925) he makes a generalization concerning the path taken by the nerves which grow out towards the hind limb. All nerves which grow into the limb, and form in it a more or less complete plexus are found in the region dorsal and lateral to the girdle in close connection with the ischiadic artery. These, however, which do not penetrate the limb-bud, are not influenced by blood vessels, and chiefly grow along the peritoneal wall. Both these types of behaviour can be interpreted as contact reactions. HAMBURGER finds that in the developing limb of the frog, blood vessels are present before nerves have found their way into the limb bud, and says " Verschiedene Beobachtungen . . . . machen es sehr wahrscheinlich, dass Blutgefässe, und zwar die Hauptarterien, den Hauptnervenstämmen als Leitwege dienen, dass an ihnen die ankommenden Nerven entlang wachsen und dass durch die Aufgabelung der Blutgefässe auch die Hauptverzweigungen der Beinnerven bedingt sind." Similar results were obtained by TELLO (1922) in a study of the hind limb-bud of the chick. We may therefore assume it to be generally true that in the hind limb-bud blood vessels are present before nerves, and that the latter follow the path of the former into the limb-bud.

This we can compare with conditions which have been found to hold in the chick head. First, there is the type of developmental relationship exemplified by that of the capillary plexus of the primary sympathetic chain. The primary sympathetic chain is present in the chick from the stage of four days, and loses its identity as a longitudinal cord towards the eighth day of incubation. It acquires an investing capillary plexus during the sixth day. The secondary sympathetic chain appears during the seventh day, and its capillary plexus follows it almost at once. Other examples of the condition where a nervous structure is present before an investing capillary plexus is acquired are not hard to seek. The extension of the general plexus of the brain down the trigeminal ganglion and nerves is one and the investment of the palatine branch of the facial with a capillary plexus of the internal carotid is another. A third type of relation is exemplified by the connection of the temporal rete with that vein which connects the head vein with the sinus of the sella turcica, where a venule grows along an artery (the ophthalmic division of the stapedial) which has remained unaccompanied during earlier stages. Perhaps the most complicated relation of all is that of the V. carotis, the internal carotid artery, and the sympathetic trunk of the head within the carotid canal. The internal carotid artery is the first of these three to be formed, the sympathetic nerve grows along it later, and much later still the venules which will form the V. carotis. A final example is one in which no nerve takes part in the relationship.

The root of the stapedial artery at first runs into the head vein in this region, but later severs this connection to run forwards as a capillary beneath, and in intimate contact with the head vein.

These examples are intended to illustrate the theory that nerves and both types of blood vessel show this postulated contact reaction to an equal degree. This type of hypothesis has the further advantage that whereas blood vessels and nerves are presumably not physiologically equivalent in the part they play in and their reaction towards grades of oxygen tension and so forth within organs, yet their selection of path taken during growth appears to be governed by identical principles. Thus were we to adopt an hypothesis that the path taken by a nerve fibre was determined by gradients of oxygen tension, the fact that the behaviour of blood vessels, which presumably condition such gradients, appears to be similar to that of nerves would form an insuperable obstacle to such a theory.

The adoption of an outlook upon the development of blood vessels such as that outlined above would discourage the investment of any particular capillary with special morphological significance, such as was done by FLEMING, who saw in a capillary which he found growing forwards from the dorsal end of the third aortic arch the representative of the external carotid of the Dipnoi. What might be termed the " left wing attitude " of an extreme upholder of THOMA's position towards the morphological relationship of any particular capillary would be that this was entirely dependent upon the way in which the capillary in question fitted into the morphological plan of its surroundings. This position provides an easy explanation of the phenomenon of variability. In the formation of a definitive vessel between two points from a capillary plexus connecting them, it is easy to see that any one of a number of capillary channels could be selected for elaboration into a vessel of greater calibre and thicker wall. That variability can indeed be explained along these lines is rendered probable by the correspondence to which attention was drawn in the section devoted to encephalic arteries, between variability within a single type and within a group with respect to the same vascular feature. Certain zones are prone to such variability, and these zones remain constant for a group of allied forms.

Yet, on the other hand, certain capillaries can be recognized in identical positions in whole series of embryos. I have observed the root of the stapedial in identical relationships with surrounding structures in upwards of a dozen embryos round about the same age. The relationship between the posterior cerebral vein and the root of the external occipital vein shows a similar constancy. Therefore, in assigning special morphological significance to any particular capillary channel, we should first ascertain the degree of constancy which it maintains in a large series of examples.

This brings us to one more philosophical question. Does morphological specificity reside intrinsically in a particular structure, for example, a capillary, or is it a function of its surroundings ? Another aspect of this question is the nature of the mechanism by which such developmental changes as the alteration in length of a vessel are brought about, such as occurs in the dorsal aorta, during the backward migration of the aortic arches. Does the dorsal aorta shorten of itself in a particular region, or is this shortening imposed upon it from without? The only statement that can be made with the evidence before one is that the different processes o development are so intimately dovetailed together that, short of the application o the experimental method to effect a separation of these different processes, however partial, any serious discussion of this point must await such experimental study. Certain it is that during the backward migration of the arches, several separate processes can be seen to converge towards a common end. Backward migration conditions the possibility of a short secondary subclavian, and of the linking of the Arteria cervicalis communis with a branch of the dorsal aorta in the eighteenth interspace to form the root of the vertebral artery.

Within recent years, perhaps the most noteworthy contribution in this general field has been that of SHELLSHEAR (1920, 1927, 1929), whose work on the arterial distribution of the brain has led to certain general conclusions of application to the vascular system generally. SHELLSHEAR distinguishes between arteries of supply, the ultimate branches of the arterial vessels, and arteries of intermediate distribution, connecting the former with the main arteries of the body. The former, according to SHELLSHEAR, are developed *in situ* with the organs which they supply, forming " vessel-end organ units " analogous to nerve-end organ units such as are formed by a sense organ and its nerve, both of which develop from a common placode. There is thus necessarily a rigid constancy of association between artery of supply and end-organ. The arteries of supply, however, are developed in no such intimate association with other structures, and in them is the seat of the variability of blood vessels, which obscures the real constancy of association between end organ and artery of supply, the latter of which is never disclosed by the ordinary methods of anatomical study.

On this foundation, SHELLSHEAR builds several further hypotheses. The first is that the arteries of supply are to be identified with the segmental arteries, developed *in situ* with the organ they are to supply. Secondly, that there is a correlation between the final pattern of arterial distribution into which the segmental arteries are woven, and the function of the organs whose arteries of supply the segmental arteries become. This correlation is expressed by limitation of the extent to which inter-segmental anastomosis can take place between segmental arteries. Thus to quote from SHELLSHEAR, " all segmental arteries are end arteries and are distributed to areas of functional value. All arteries which retain their segmental value are distributed to one area of function and are end arteries within that area; all intersegmental links take place between areas of the same function "—" all arterial anastomoses in the body connect areas of similar function. Areas of dissimilar function are connected by capillaries."

These ideas have suggested themselves to SHELLSHEAR as the explanation of the results of his comparative studies on the arterial distribution of the fore-brain, which he summarizes as follows: " When a primitive functional area develops greater function, the vessels supplying the greater functioning area are derived from those supplying the primitive area."

The most immediate criticism of SHELLSHEAR's angiological philosophy which suggests itself is that these ideas do not harmonize with what is known of the development of the vascular system. In the first place, although the variability in arterial distribution, due to the condensation of the arteries of intermediate distribution into links between the arteries of supply and the main arteries of the body along a number of alternate paths, harmonizes very well with what is known concerning the development of definitive vessels from capillary plexus, it would be exceedingly difficult to demonstrate embryologically the " vessel-end organ unit."* The writer feels that SHELLSHEAR's conception of a segmental artery is at variance with the facts of development. In the first place, these vessels are not segmental, but intersomitic. Secondly, that they do not owe their position to any " will to segmentation " on the part of the embryo, but to the fact that when they arise, and for a considerable period to come, the somites are non-vascular areas, and the only possible sites of vessels distributing arterial blood to the dorsal region of the body are in between the somites. Where blood vessels are arranged metamerically, the somites are responsible for this arrangement ; thus in a six day chick, where a capillary plexus spreads outwards from the intersomitic vessels into the region lateral to the somites, it does so entirely without any reference to the somites. Again, as soon as the cephalic somites become indistinct, the intersomitic vessels in that region lose their definition also.

SHELLSHEAR, indeed, hedges on the question whether the head region is to be regarded as a segmental structure. Even in the scanty observations which were made in the course of the present study on the development of the vascular system within the brain, it was clear that no direct relations with a segmental plan could be demonstrated, and that, moreover, the central nervous system is at first a non-vascular area, its arteries of supply being acquired by penetration. This penetration takes place in the head region of the chick during the fifth day of incubation.

One is very ready, nevertheless, to subscribe to SHELLSHEAR's basal idea of the " constancy in inconstancy " of arterial distribution, despite the difficulties of accepting the superstructure of ancillary hypotheses. Moreover, he recognizes the close connection that exists between the laws underlying the respective distributions of blood vessels and nerves. For SHELLSHEAR, the arteries and the sympathetic nervous system constitute a vessel-end organ unit. Again we may raise the embryological objection of the disparity in the time of appearance between these two sets of structures, yet the important point is the recognition of the connection, apart from the nature of the ultimate causative relation between them.

---

* There is some evidence that differentiation of vascular tissue can take place isolated from the main blood stream. This takes place to a very large extent in the metanephros (RIENHOFF, 1922), and, moreover, SABIN (1920) has shown that a few isolated angioblasts can join up with the differentiating dorsal aorta. We do not know, however, how far such conditions are general within the embryo.

SHELLSHEAR goes so far as to state that " it is the distribution of the sympathetic nervous system which governs the distribution of the blood vessels," a conclusion which the writer feels is unlikely to be substantiated by future work. For such future work, however, we must wait before this subject can profitably be further discussed.

V—SUMMARY

The development of the head vessels of the chick is described from the stage of twenty-nine somites to that of hatching. The method employed in this study has been that of injection of the living embryo, followed either by rendering the tissues transparent in a whole mount, or by the preparation of serial sections.

The attempt has been made, whenever possible, to trace definitive blood vessels from an antecedent capillary plexus, as well as to study their changes subsequent to the attainment of definitive form. No facts contrary to the view that blood vessels are in general preceded by an antecedent capillary plexus have been disclosed.

The tracing of veins and arteries from a common antecedent plexus has disclosed relationships which could only receive recognition in a study which dealt with both types of blood vessel. The necessity for such simultaneous study is emphasized.

Such relationships are part of other general relations into which nerves enter as well. Various types of association between arteries, veins, and nerves are instanced and discussed. A nerve may be the first formed structure, around which a capillary plexus will form, out of which an artery and vein may differentiate, or nerves may enter an organ along the path of already present capillaries.

The hypothesis is tentatively advanced that these phenomena are to be regarded as the effects of a contact reaction common to both vascular and nervous structures.

It is suggested that the forces governing the path taken during development by both nerve and blood vessel are similar. A study is made of the variability in morphological relationship encountered in one particular region in both types of structure, and this variability is regarded as of the same kind.

Considerable reserve is advocated in investing particular vascular channels with special morphological significance. It is suggested that such speculation should always be preceded by intensive study of the variability encountered in the particular area.

A particular example of such morphological speculation which appears to be well founded is the derivation of the stapedial artery from the dorsal section of the hyoid arterial arch. In the chick, any such definite association with the mandibular arch seems less clear.

The attempt has been made to prepare the way for an experimental study of the backward migration of the aortic arches. Several facts of the manner in which this takes place are disclosed by observational study.

The theoretical ideas of SHELLSHEAR concerning the laws underlying the development of blood vessels are discussed.

VI—REFERENCES

BAKST, H. J., and CHAFEE, F. H. (1928). ' Anat. Rec.,' vol. **38**.

BEDDARD, E. (1905). ' Proc. Zool. Soc. Lond.,' vol. **1**.

CHAPMAN, W. B. (1918). ' Amer. J. Anat.,' vol. **23**.

CLARK, E. R. (1918). ' Amer. J. Anat.,' vol. **23**.

ELZE, C. (1913). ' Anat. Anz.' vol. **44**.

EVANS, H. M. (1909). ' Amer. J. Anat.,' vol. **9**.

FLEMING, I. E. (1926). ' Anat. Rec.,' vol. **33**.

GADOW, H., and SELENKA, E. (1891). In BRONN, H. G., " Thier Reich," vol. **6**, pt. 4, ' Aves.'

VAN GELDEREN, C. (1924). ' Z. ges. Anat., 1, Z. Anat. EntwGesch.,' vol. **74**.

HAFFERL, A. (1921, *a*). ' Anat. Hefte,' vol. **59**.

—— (1921, *b*). *Ibid.*

HAMBURGER, V. (1929). ' Z. Wiss. Biol., Abt. D., EntwMech.,' vol. **119**.

HIS, W. (1900). ' Abh. sächs. Ges. (Akad.) Wiss.,' vol. **26**.

HOFMANN, M. (1900). ' Z. Morphol. Anthropol.,' vol. **2**.

KASTSCHENKO, N. (1887). ' Arch. Anat. Physiol.'

KNOWER, H. (1908). ' Anat. Rec.,' vol. **2**.

KRASSNIG, M. (1913). ' Anat. Hefte,' vol. **49**.

LILLIE, F. R. (1919). " The Development of the Chick," New York.

MALL, F. B. (1904). ' Amer. J. Anat.,' vol. **4**.

MCCLURE, C. F. W. (1921). ' Anat. Rec.,' vol. **22**.

MCWHORTER, J. E., and WHIPPLE, A. O. (1912). ' Anat. Rec.,' vol. **6**.

NEUGEBAUR, L. A. (1844). ' Nov. Act. Acad. Leop. Carol.,' vol. **21**.

PETERS, K. (1906). " Die Methoden der Rekonstruction," Jena.

POPOFF, D. (1894). ' Die Dottersack-Gefässe des Huhnes,' Wiesbaden.

RATKE, H. (1838). " Ueber den Bau und die Entwickelung des Venensystems der Wirbelthiere," Königsberg.

RIENHOFF, W. F. (1922). ' Bull. Johns Hopkins Hosp.,' vol. **33**.

ROUX, W. (1879). ' Gesamm. Abh.'

SABIN, C. G. (1905). ' Anat. Anz.,' vol. **26**.

SABIN, F. (1915). ' Contr. Embryol. Carn. Instn.,' **7**.

—— (1917). ' Contr. Embryol. Carn. Instn.,' 18.

—— (1920). ' Contr. Embryol. Carn. Instn.,' 36.

SHELLSHEAR, J. L. (1920). ' J. Anat. Lond.,' vol. **55**.

—— (1927). ' J. Anat. Lond.,' vol. **61**.

—— (1929). ' Phil. Trans. B.,' vol. **218**.

STREETER, G. L. (1918). ' Contr. Embryol. Carn. Instn.,' 24.

TANDLER, J. (1902). ' Morph. Jahrb.,' vol. **30**.

TELLO, J. F. (1922). ' Z. ges. Anat. 1, Z. Anat. EntwGesch.,' vol. **64**.

TWINING, G. H. (1906). ' Anat. Anz.,' vol. **29**.

VII—Key to Lettering

a.i.5, etc., artery of the fifth, etc., interspace.
a.m., adductor mandibulæ.
a.o.a., ascending œsophageal artery.
a.p.c.a., anterior ramus of the posterior cerebral artery.
ab.m., abductor mandibulæ.
ant.c.a., anterior cerebral artery.
ant.c.v., anterior cerebral vein.
ant.c.v.r., root of anterior cerebral vein.
ant.h.v., main head vein in the orbit.
ao.a.l., etc., first, etc., aortic arch.
at., atlas.
au.a., auricular artery.
ax., axis.

b.t., basitemporal.
ba.a., basilar artery.
bi.a., bigeminal artery.

c.c.a., common carotid artery.
c.c.b., base of cranial cavity.
c.g., ciliary ganglion.
c.v., carotid vein.
ce.a., cerebellar artery.
cau.c.W., caudal ramus of the circle of Willis.
cr.c.W., cranial ramus of the circle of Willis.
com.c.a., communal cervical artery.

d.C., duct of Cuvier.
d.o.a., descending œsophageal artery.

eth.oph.ce., anastomosis between cerebral ophthalmic and ethmoidal artery.
eth.v., ethmoidal vein.
ext.c.a., external carotid artery.
ext.eth.a., external ethmoidal artery.
ext.f.a., external facial artery.
ext.f.a.u., uprising branch from external facial artery.
ext.f.v., external facial vein.
ext.occ.v., external occipital vein.
ext.occ.v.d., origin of external occipital vein from mid-dorsal sinus.
ext.oph.ce., connective between ethmoidal artery and cerebral ophthalmic.
eye.p., plexus surrounding the eyeball.

f.v., floccular vein.

gen.IX., glossopharyngeal nerve to geniohyoid muscle.
h.s.c., horizontal semi-circular canal.
hy.a., hyoidean artery.
hy.v.p., hyoid visceral pouch.
hym.VII., hyomandibular branch of facial.
hyp., hypophysis.

i.c.a., internal carotid artery.
inf.alv.v., inferior alveolar vein.
inf.V., infraorbital ramus of trigeminal.
int.eth.a., internal ethmoidal artery.
int.mx.u., upper internal maxillary artery.
int.mx.m., middle internal maxillary artery.
int.mx.i., lower internal maxillary artery.

j.v., main jugular vein.

l.IX., laryngeal branch of the glossopharyngeal.
l.10, etc., level of the section drawn in fig. 10, Plate 5, etc.
l.b.i.v., lateral branch from intersomitic veins.
l.c., cavity for lagena.
l.h.v.X., lateral head vein in the region of the vagus.
l.occ.v., lateral occipital vein.
l.v., laryngeal vein.
li.a., lingual artery.

md., mandible.
md.V., maxillo-mandibular ramus of the trigeminal.
md.r., mandibular ramus of the external carotid.

VII—Key to Lettering (*continued*).

mid.c.a., middle cerebral artery.
mid.c.a.c.p., branch of middle cerebral artery to anterior choroid plexus.
mid.c.v., middle cerebral vein.
mid.d.c.s., mid-dorsal cervical sinus.
mid.d.s., mid-dorsal head sinus.
mid.d.s.a., anterior prolongations of mid-dorsal sinus which ultimately connect with ethmoidal vein on each side.
mid.d.s.c.p., vein from mid-dorsal sinus to anterior choroid plexus.
mx.ext., maxillary extension of the superficial plexus of the mandibular arch.
mx.r., maxillary ramus of the external carotid, formed from mx.ext.
mx.v., maxillary vein.

o.s., orbitosphenoid.
o.s.g., otic sympathetic ganglion.
occ.a., occipital artery.
occ.a.l., lateral branches of occipital artery to neck musculature.
occ.a.m., anterior median branch of occipital artery.
occ.a.v., occipital artery forming root of vertebral artery.
occ.v., occipital vein.
olf.inv., olfactory invagination.
oph.V., ophthalmic ramus of the trigeminal.
oph.a.c.v., ophthalmic prolongation of anterior cerebral vein.
oph.a.c.v.(2), ophthalmic prolongation of anterior cerebral vein, when connection with the latter has been lost.
oph.ce., cerebral ophthalmic artery.
oph.ce.(2), cerebral ophthalmic artery.
oph.i.c., ophthalmic branch of the internal carotid.
oph.st., ophthalmic branch of the stapedial artery.
ot., otocyst.
out.md., outline of mandible.

p.a., pulmonary artery.
p.b.p., primary body wall plexus.
p.c.a., posterior cerebral artery.
p.c.h., posterior cornu of the hyoid.
p.p.c.a., posterior ramus of the posterior cerebral artery.
p.St.(1), primary Stammvene, as yet complete.
p.St.(2), primary Stammvene, having lost anterior connection.
p.St.a.(1), anterior root of primary Stammvene.
p.St.a.(2), anterior root of primary Stammvene, now running into temporal rete.
p.sub.a., primary subclavian artery.
p.sy.c., primary sympathetic cord.
p.sy.pl., primary sympathetic plexus.
p.t.c.(1), pretympanic connective between primary and secondary Stammvenen.
p.t.c.(2), pretympanic connective, now joined only to secondary Stammvene.
pal.VII, palatine branch of the facial.
pal.a., palatine branch of the facial.
pal.v., palatine vein.
post.c.v., posterior cerebral vein.
pt., pterygoid.
pt.q., pterygoid process of the quadrate.

q.j., quadrato-jugal.

s.e., saccus endolymphaticus.
s.i., saccus infundibuli.
*s.g.*10, etc., tenth, etc., spinal ganglion.
s.l.a., superior laryngeal artery.
s.t.s., sinus of sella turcica.
s.t.s.v., vein which will ultimately run to the sinus of the sella turcica.
sec.ext.c.rt., root of the secondary external carotid.
sec.St., secondary Stammvene.
sec.St.p.r., posterior root of the secondary Stammvene.
sec.sub.(1), secondary subclavian, as yet discharging into the duct of Cuvier.

VII—Key to Lettering (*continued*).

sec.sub.(1) *rt.*, superseded connection of the secondary subclavian and the duct of Cuvier.
sec.sub.(2), definitive secondary subclavian artery.
sec.sy.c., secondary sympathetic cord.
sec.sy.pl., secondary sympathetic plexus.
sph.-.m.a., spheno-maxillary artery
sph-m.a.mx., connective between spheno-maxillary artery and middle internal maxillary artery.
st., stapes.
st.a., stapedial artery.
st.rt., stapedial root.
st.alv., inferior alveolar ramus of the stapedial.
st.inf., infraorbital ramus of the stapedial.
st.sup., supraorbital ramus of the stapedial.
st.te., temporal ramus of the stapedial.
su.p.m.a., superficial plexus of the mandibular arch.
su.p.hy.a., superficial plexus of the hyoid arch.
t.r., temporal rete.
t.r.v., vein from the temporal rete running with the ophthalmic ramus of the stapedial.
te.m., temporal muscle.
th.a., thyroid artery.
tr.l., transverse vein of the first interspace.
trab., procartilaginous trabeculæ.
ty.c., tympanic cavity.
ty.m., tympanic membrane.

v.a., definitive root of the vertebral artery.
v.ch.f., vein of the choroid fissure.
v.i.5, *etc.*, vein of the fifth, etc., interspace.
v.v., vertebral vein.
v., *l.c.v.*, junction of vertebral and lateral occipital veins.
vag.a., vagus artery.

DESCRIPTION OF PLATES

The Magnifications given refer to the Plates.

PLATE 1

FIG. 1—Reproduction of Miss SABIN's Plate 6, of a chick embryo of twenty-nine somites. Right side. The legend thereto is as follows :—

The vena capitis prima arises in three segments :—

1. (*v.cap.p.*1.) a true primitive cerebral vein, draining the fore-brain, and will soon drain the mid-brain.
2. (*v.cap.p.*2) an anastomosis between maxillary, mandibular, the other visceral arches, and the anterior cardinal vein, draining the brain and the visceral arches.
3. (*v.cap.p.*3) the anterior cardinal vein, draining the brain and the visceral arches.

A.b., artery on the rhombencephalon, bilateral at this stage, and part of a plexus which will give rise to the basilar artery.
*A.*3., artery to the medulla in the third interspace.
d.C., ductus Cuvieri.
v.c.p., posterior cardinal vein.
v.m.p., vena maxillaris primitiva.
v.om., omphalo-mesenteric vein.
v.t., transverse vein of the first interspace.
v.u., plexus in which umbilical vein will arise.
va.p.r., vasa primitiva rhombencephali.
ves.a., auditory vesicle.

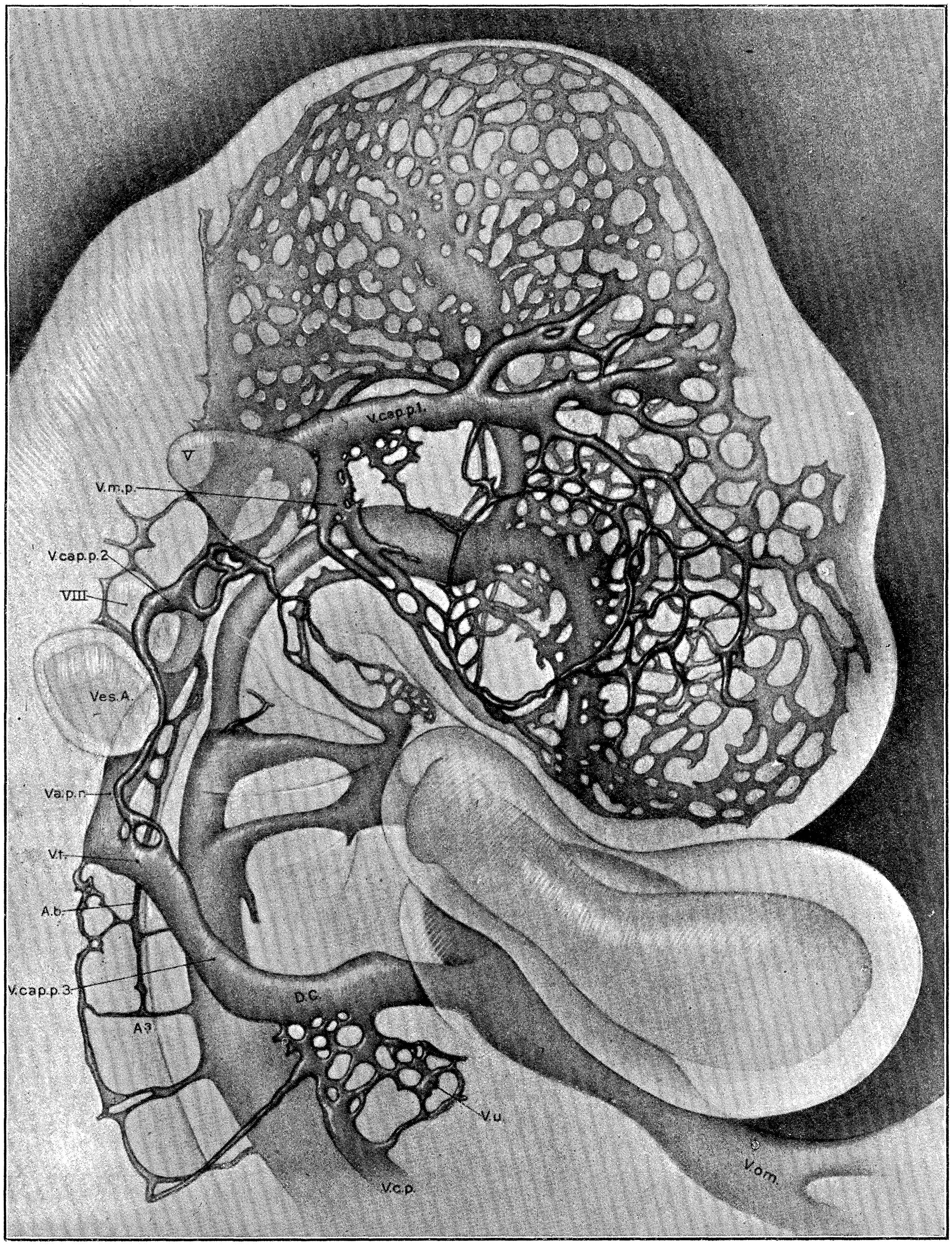
V.cap.p.1.
V
V.m.p.
V.cap.p.2
VIII
Ves.A.
Va.p.n.
V.t.
A.b.
V.cap.p.3
A3
D.C.
V.u.
V.c.p.
V.om.

FIG. 1

PLATE 2

FIG. 2—The head vessels of a chick embryo of thirty somites, reconstructed from sections. It corresponds to a stage in their development a little later than that of fig. 1, in that the lateral head vein in the region of the auditory vesicle is now larger than the medial vessel in the same region. The medial vessel has a vertically directed branch in front, and the lateral vessel one behind the auditory vesicle. Left side. × 38.

FIG. 3—Drawing of a transparency of a chick embryo of thirty-two somites. In this specimen, no medial head vein could be recognized, possibly due to it remaining uninjected, yet the vertically directed branch which sprang from it at the stage of fig. 2 was injected, and now connects with lateral head vein. The first aortic arch is represented by a capillary which now runs into the dorsal carotid in front of the first pharyngeal pouch, which in figs. 1 and 2 ran into the lateral head vein. The superficial plexus of the mandibular arch has begun to develop. Left side. × 38.

FIG. 4—Drawing of a transparency of a chick embryo of thirty-two somites, in which the ink has lodged in the main arteries, and not in capillary plexus or veins. The ophthalmic roots of the internal carotid and cranial ramus of the circle of Willis can be seen, contributing to the plexus around the eyeball. A connection has been established between the backwardly growing plexus from the caudal ramus of the circle of Willis, along the ventral surface of the hind-brain, and the forwardly directed anastomosis between the intersomitic arteries, the which has not happened in the stage of fig. 3. Thus is formed the paired anlage of the basilar artery. Left side. × 25.

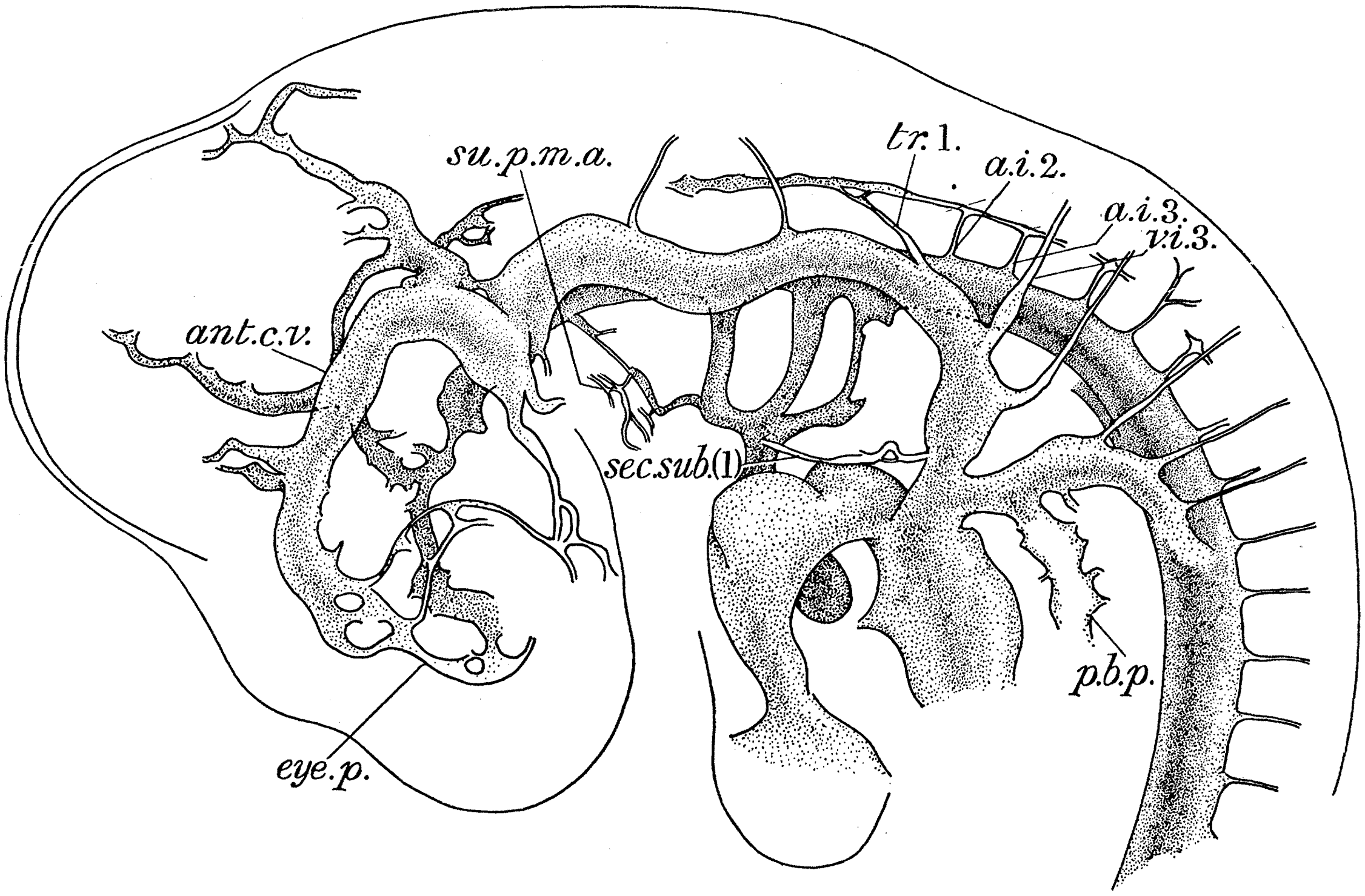

Fig. 3

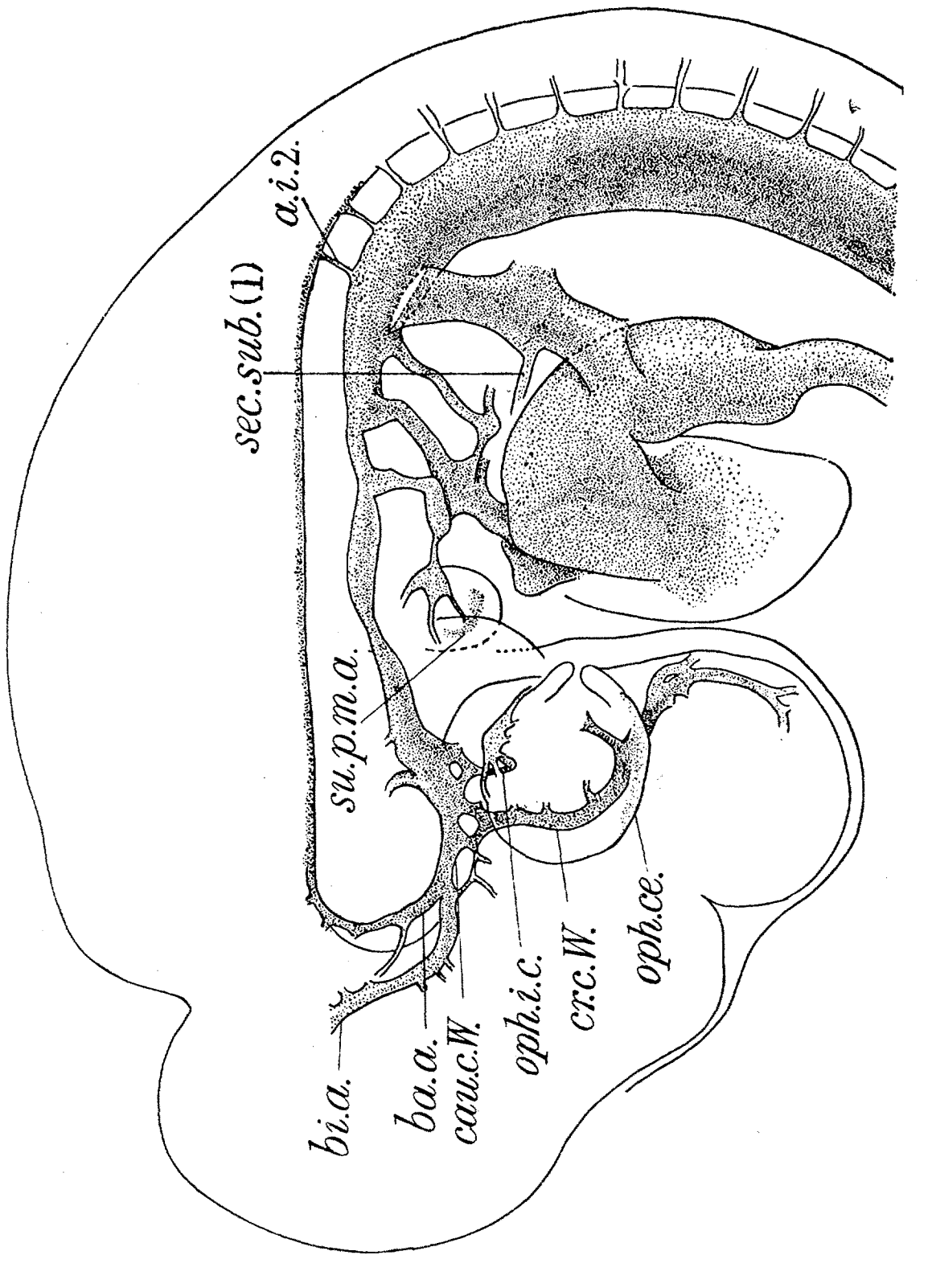

Fig. 4

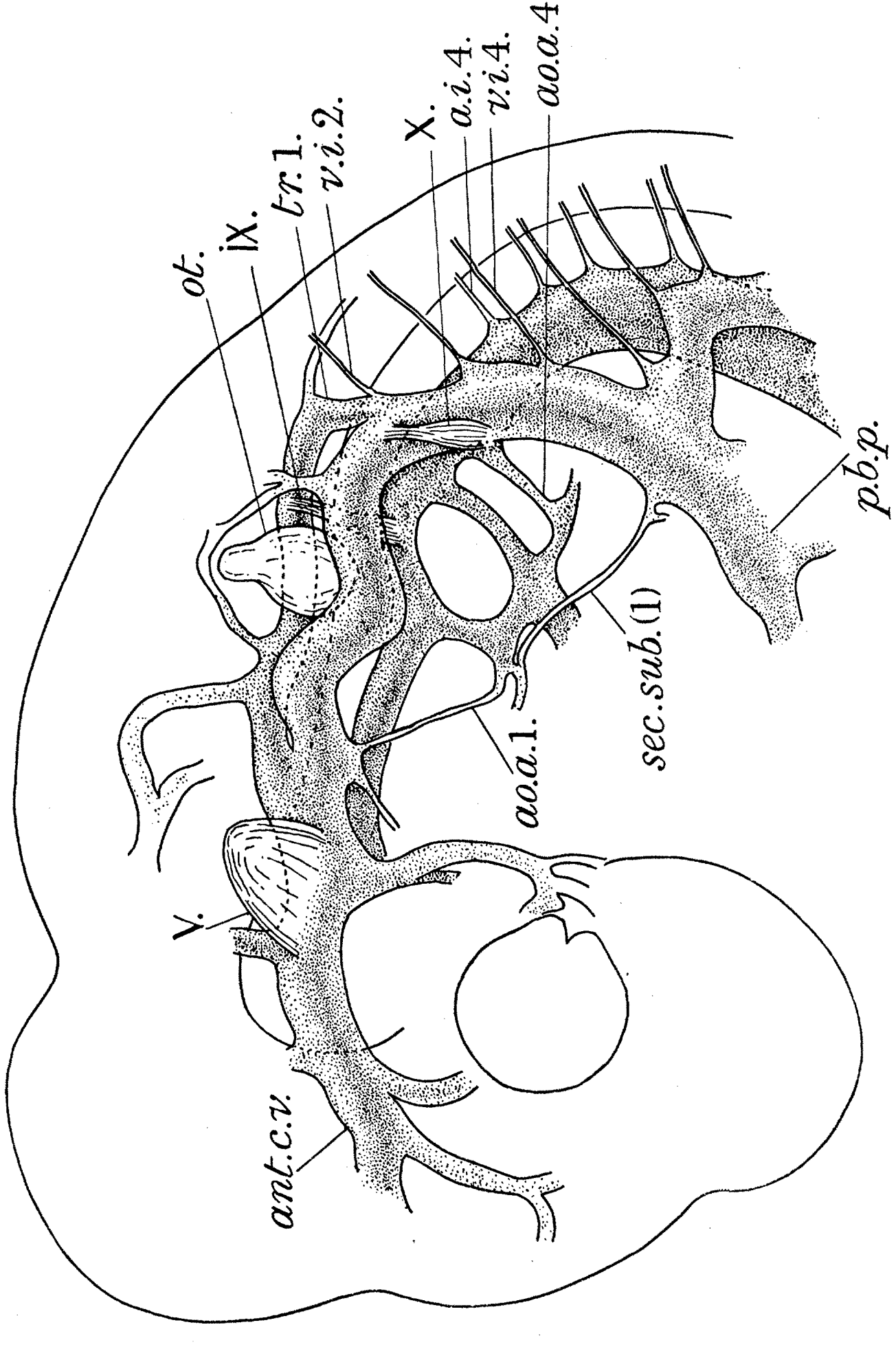

Fig. 2

PLATE 3

FIG. 5—Drawing of a transparency of a chick embryo of four days. The sixth aortic arch has appeared, and the secondary subclavian artery is seen as a superficial plexus between that of the hyoid arch, and the duct of Cuvier. It connects with the third, fourth, and sixth aortic arches at their bases. The cardinal veins are incomplete, and the plexus of the fore limb-bud is represented only in outline. Right side. × 25.

FIG. 6—Reconstruction of the main head vein of a four and a half day chick embryo. It can be seen that the vessel in front of the auditory vesicle which originally connected with the medial head vein becomes the future middle cerebral vein when connection is established with the lateral head vein. The posterior cerebral vein is the branch of the latter behind the auditory vesicle. Its level is that between the glossopharyngeal and vagus—that is, that of the transverse vein of the first interspace. A secondary connection between the external occipital root and the posterior cerebral vein causes the transverse vein of the first interspace to appear to the next intersomitic space, the lateral head vein in the neighbourhood of the vagus first appears. Left side. × 20.

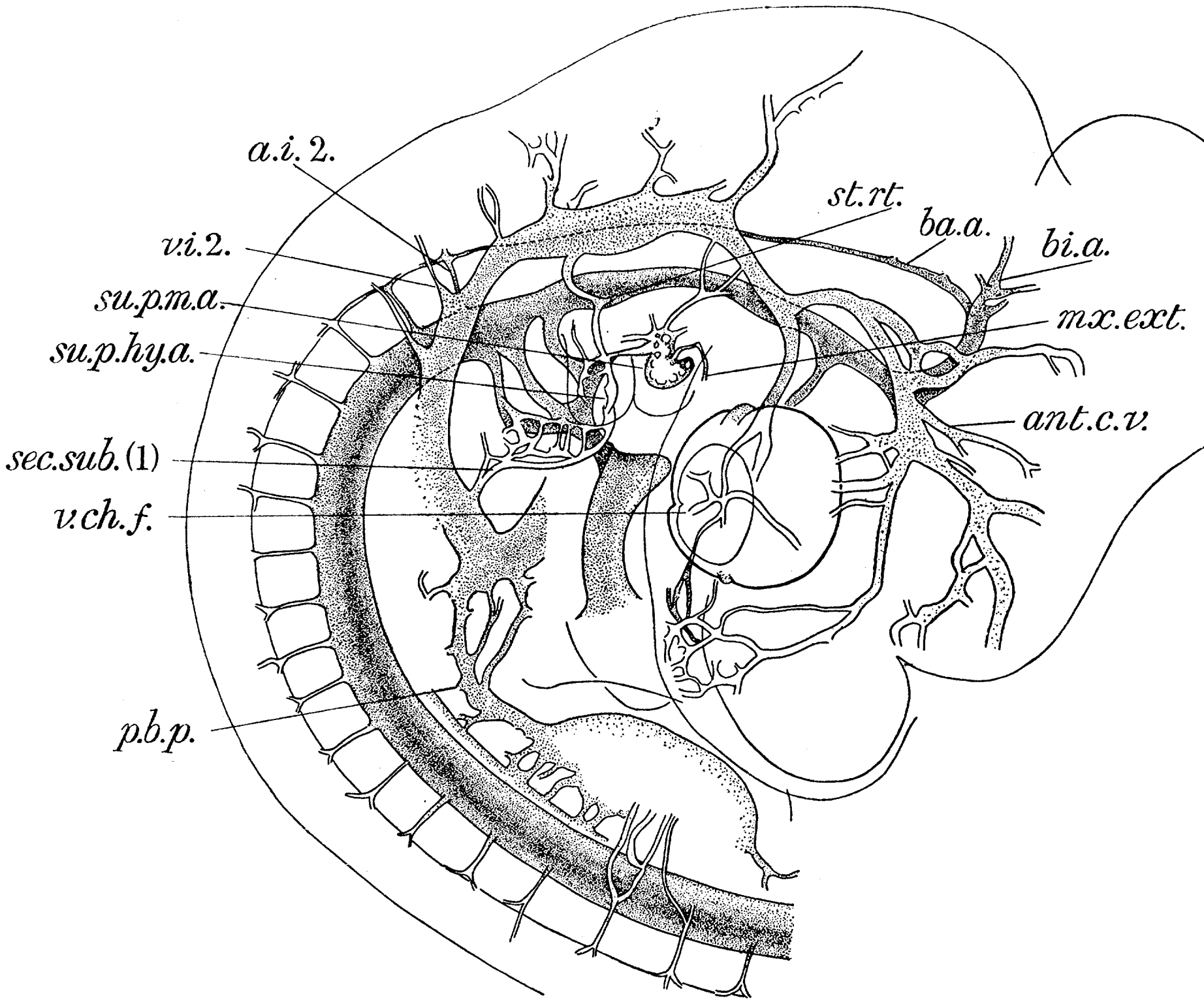
a.i.2.
v.i.2.
su.p.m.a.
su.p.hy.a.
sec.sub.(1)
v.ch.f.
p.b.p.
st.rt.
ba.a.
bi.a.
mx.ext.
ant.c.v.

FIG. 5

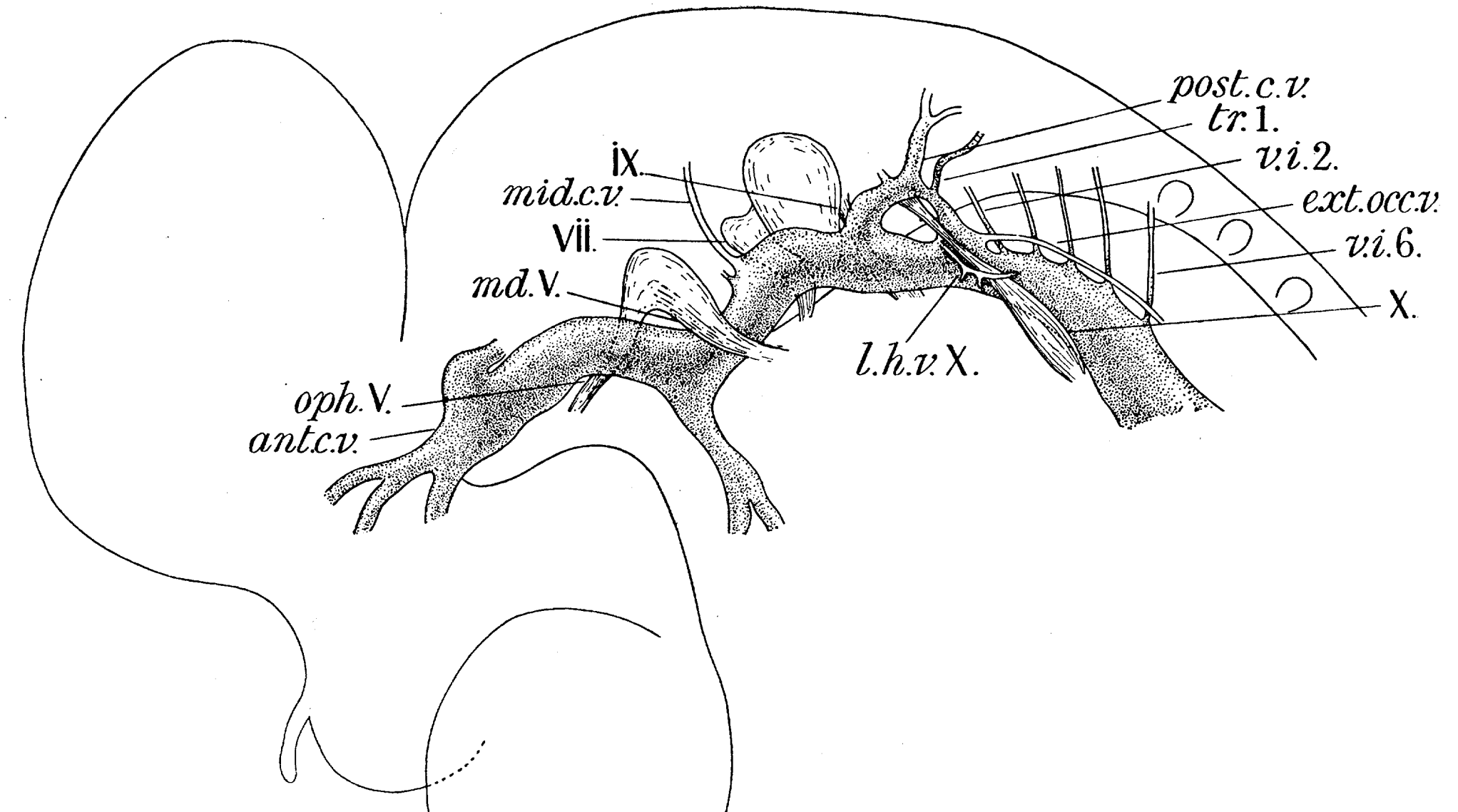
post.c.v.
tr.1.
v.i.2.
ext.occ.v.
v.i.6.
X.
IX.
mid.c.v.
VII.
md.V.
l.h.v. X.
oph.V.
ant.c.v.

FIG. 6

PLATE 4

FIG. 7—Drawing of a transparency of a chick embryo of four and a half days. The transitory fifth aortic arch has appeared. Owing to the ink not having lodged in the capillary plexus of the maxilla and mandible, it is seen that the superficial plexus of the mandibular arch has been partially resolved into a branch from the ventral aorta entering the mandible, and into one entering the maxilla. The first extension of this plexus into the maxilla is seen in fig. 5. These vessels which are below the level of the eyeball, and which are seen through the latter are unshaded. Right side. × 25.

FIG. 8—Reconstruction of the head arteries of a chick embryo of five and a half days. The secondary subclavian artery still runs into the duct of Cuvier. Left side. × 20.

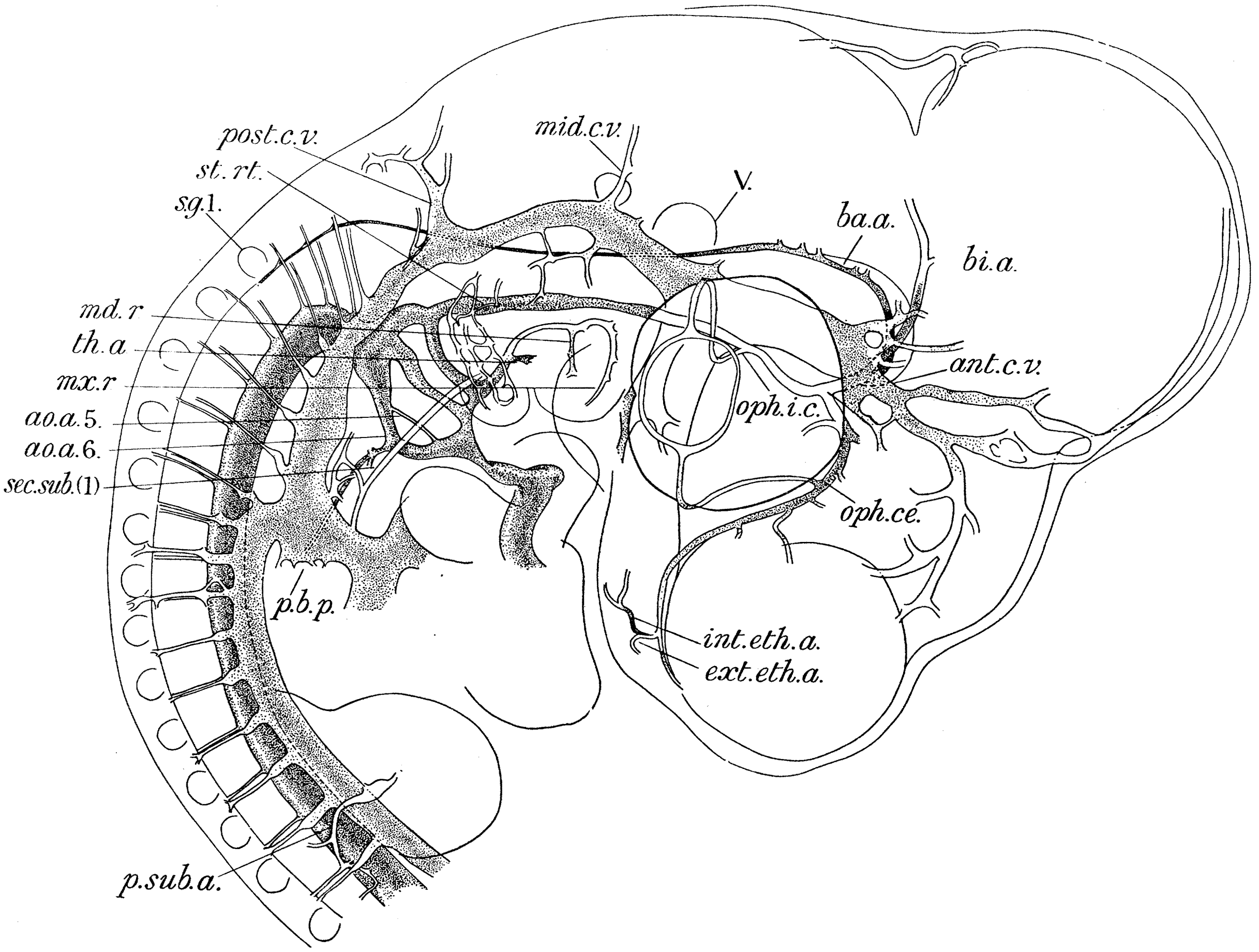
post.c.v.
mid.c.v.
st.rt.
V.
sg.1.
ba.a.
bi.a.
md.r
th.a
ant.c.v.
mx.r
ao.a.5.
ao.a.6.
oph.i.c.
sec.sub.(1)
oph.ce.
p.b.p.
int.eth.a.
ext.eth.a.
p.sub.a.

Fig. 7

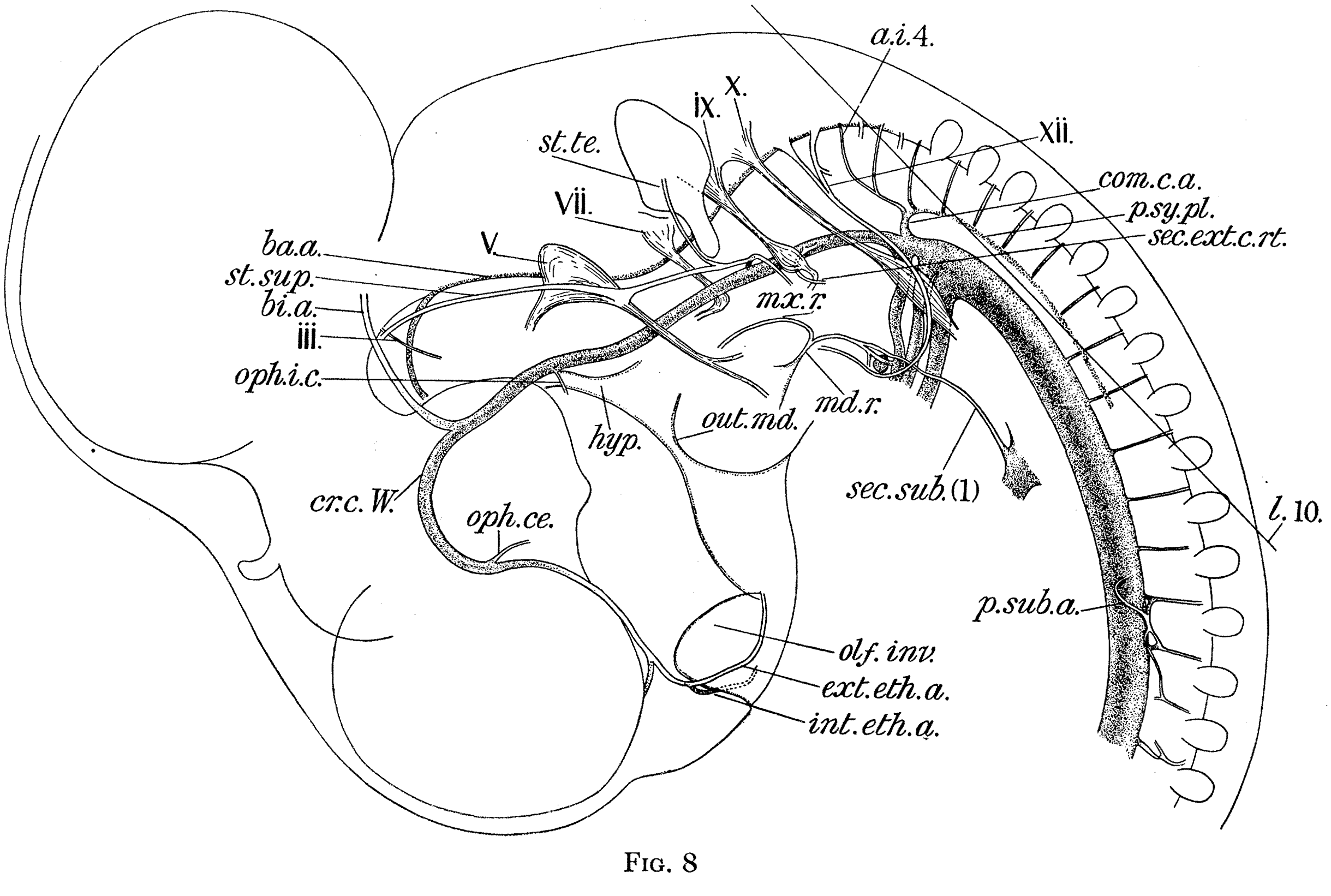
a.i.4.
IX.
X.
XII.
st.te.
com.c.a.
VII.
p.sy.pl.
sec.ext.c.rt.
ba.a.
V.
st.sup.
mx.r.
bi.a.
III.
oph.i.c.
md.r.
out.md.
hyp.
cr.c.W.
sec.sub.(1)
oph.ce.
l.10.
p.sub.a.
olf.inv.
ext.eth.a.
int.eth.a.

Fig. 8

PLATE 5

FIG. 9—Reconstruction of the head veins of the five and a half day embryo of fig. 8. The primary sympathetic plexus, seen lateral to the intersomitic arteries in fig. 8, is seen to be medial to the intersomitic veins. Left side. × 20.

FIG. 10—Section through the five and a half day embryo of figs. 8 and 9, at the level there indicated. Capillaries are represented in solid black, procartilage lightly dotted, with dotted outlines. × 31.

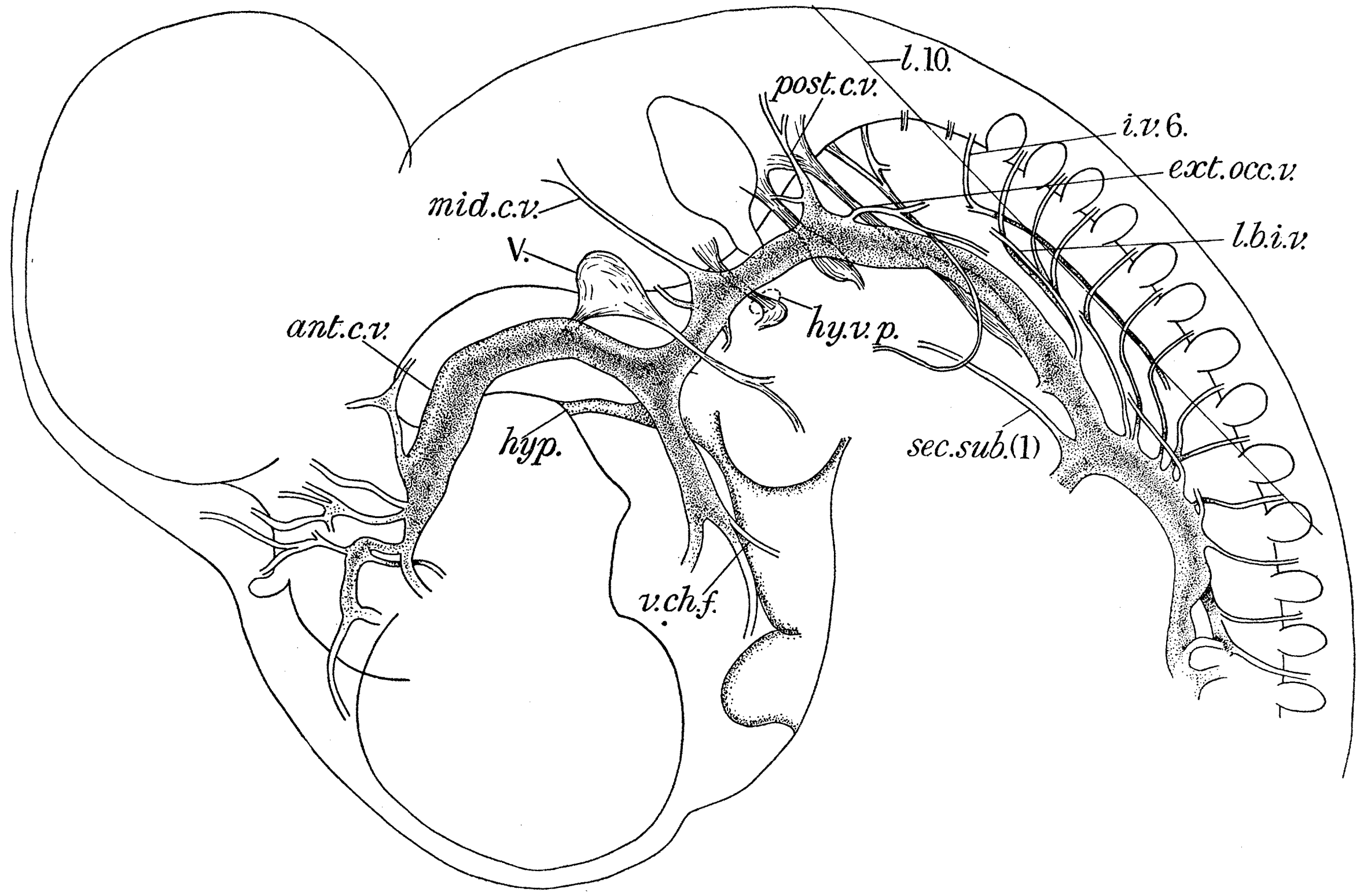
l.10.
post.c.v.
i.v.6.
ext.occ.v.
mid.c.v.
l.b.i.v.
V.
hy.v.p.
ant.c.v.
hyp.
sec.sub.(1)
v.ch.f.

Fig. 9

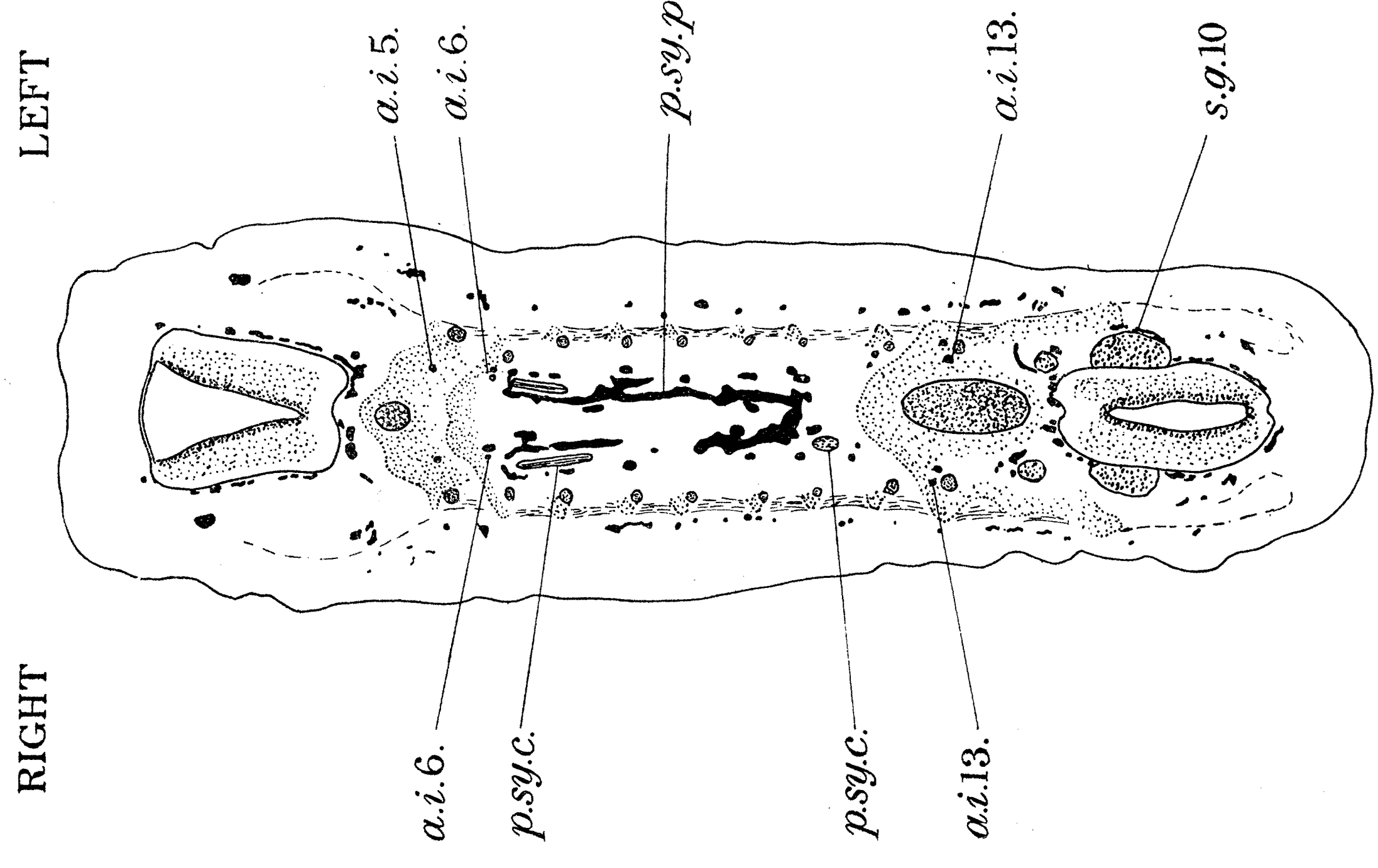
LEFT
RIGHT
a.i.5.
a.i.6.
p.sy.pl.
a.i.13.
s.g.10
a.i.6.
p.sy.c.
p.sy.c.
a.i.13.

Fig. 10

Plate 6

Fig. 11—Reconstruction of the head veins of an embryo of six and a half days. The secondary subclavian now no longer runs into the Cuvierian duct, but passes lateral thereto to enter the limb-bud. The root of the connection with the ductus still remains. Left side. × 19.

Fig. 12—Section through the hind-brain region of the six and a half day embryo of fig. 11, at the level there indicated. On the left side, the maxillary ramus of the external carotid, medial to the glossopharyngeal, has joined with the mandibular ramus which lies lateral to that nerve. The junction takes place immediately in front of the glossopharyngeal. In this, and in all succeeding representations of sections, blood vessels are represented as unshaded, with a double outline for arteries. Nerves are shaded, and the outlines of muscles are dotted. × 26.

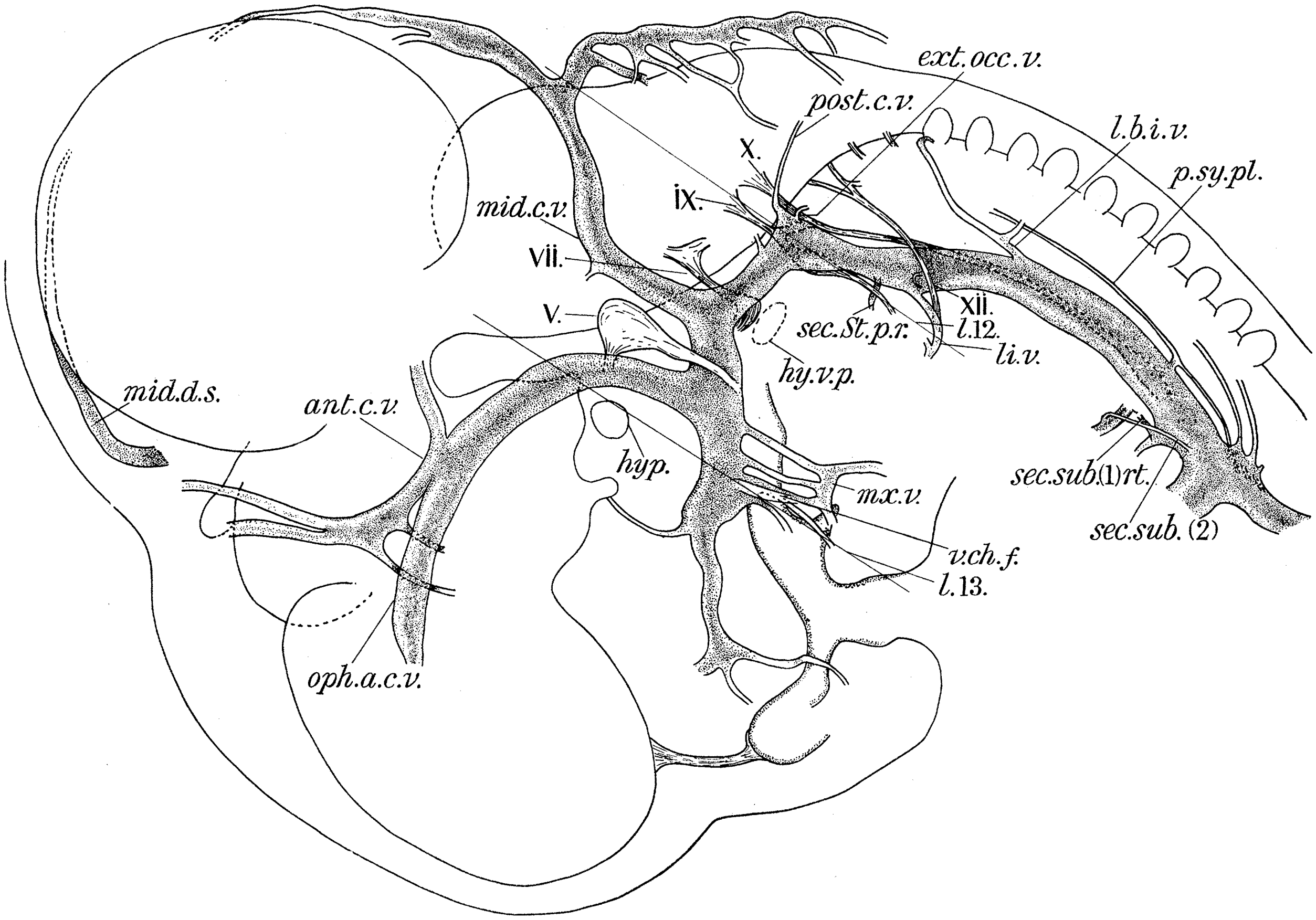
ext.occ.v.
post.c.v.
l.b.i.v.
p.sy.pl.
X.
IX.
mid.c.v.
vii.
V.
xii.
sec.St.p.r.
l.12.
li.v.
hy.v.p.
mid.d.s.
ant.c.v.
hyp.
mx.v.
sec.sub.(1)rt.
sec.sub.(2)
v.ch.f.
l.13.
oph.a.c.v.

Fig. 11

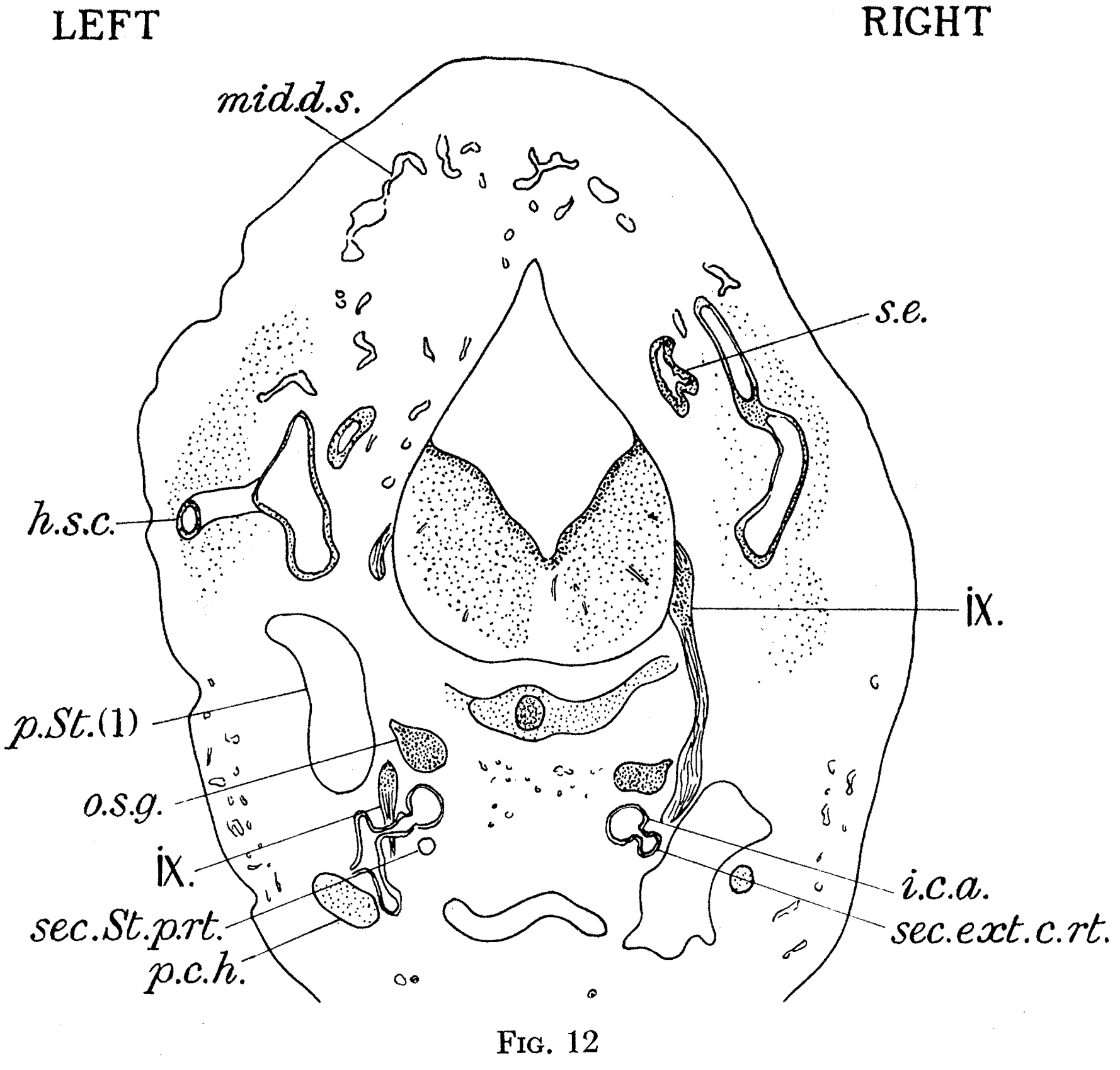
LEFT
RIGHT
mid.d.s.
s.e.
h.s.c.
IX.
p.St.(1)
o.s.g.
IX.
sec.St.p.rt.
p.c.h.
i.c.a.
sec.ext.c.rt.

Fig. 12

Plate 7

Fig. 13—Section through the hypophysial region of the embryo of fig. 11, at the level indicated in that figure. The cranium is still procartilaginous, and the hypophysis is as yet surrounded only by the general plexus covering the brain. × 23.

Fig. 14—Reconstruction of the arteries in the region of the neck of an embryo of six and a half days, with the addition of parts of the cardinal veins. The embryo is not the same as that of fig. 11. The secondary sympathetic plexus has appeared, and also the secondary external carotid root, although the ventral aorta is still complete. Left side. × 32.

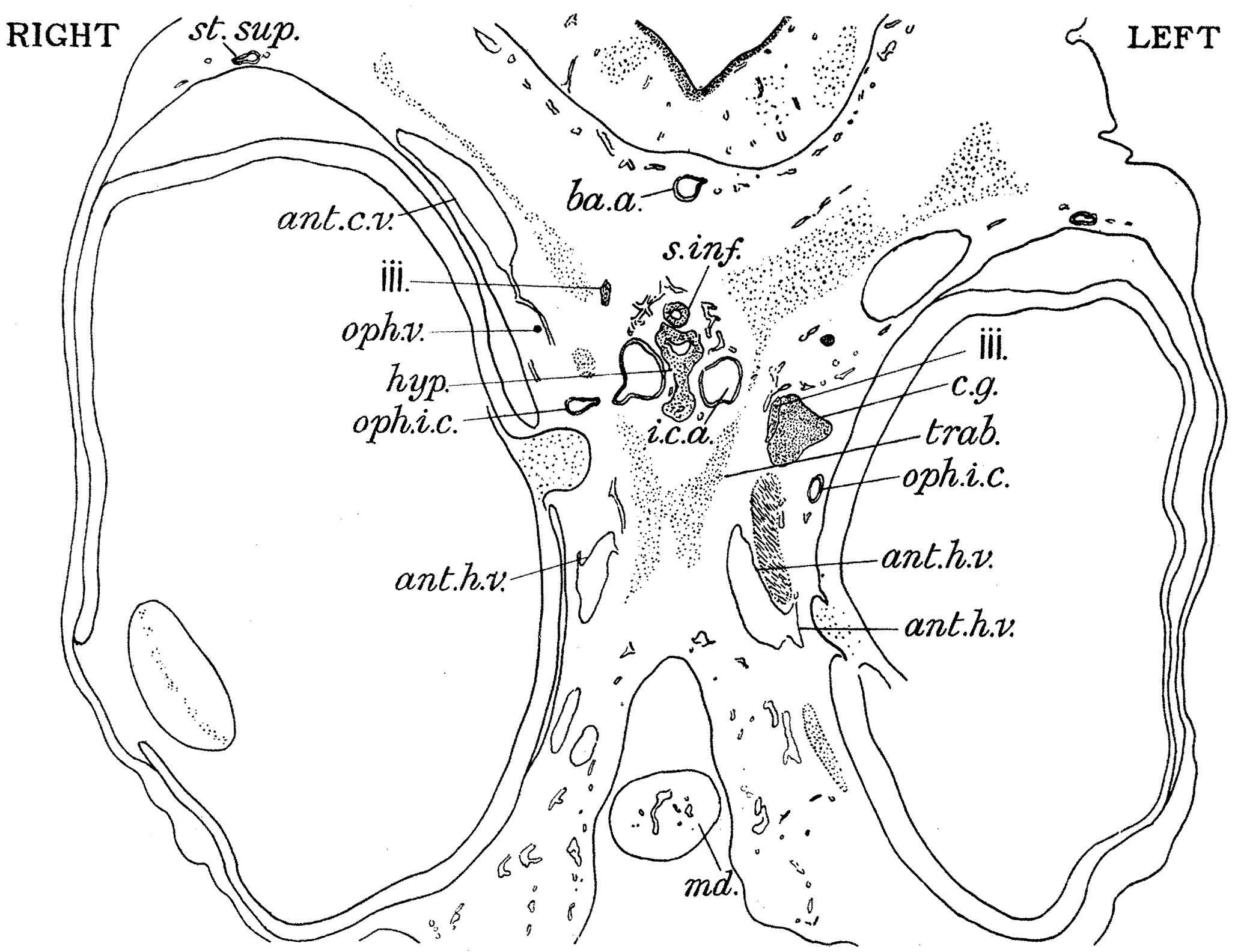
RIGHT
st. sup.
LEFT
ba.a.
ant.c.v.
s.inf.
iii.
oph.v.
iii.
hyp.
c.g.
oph.i.c.
i.c.a.
trab.
oph.i.c.
ant.h.v.
ant.h.v.
ant.h.v.
md.

Fig. 13

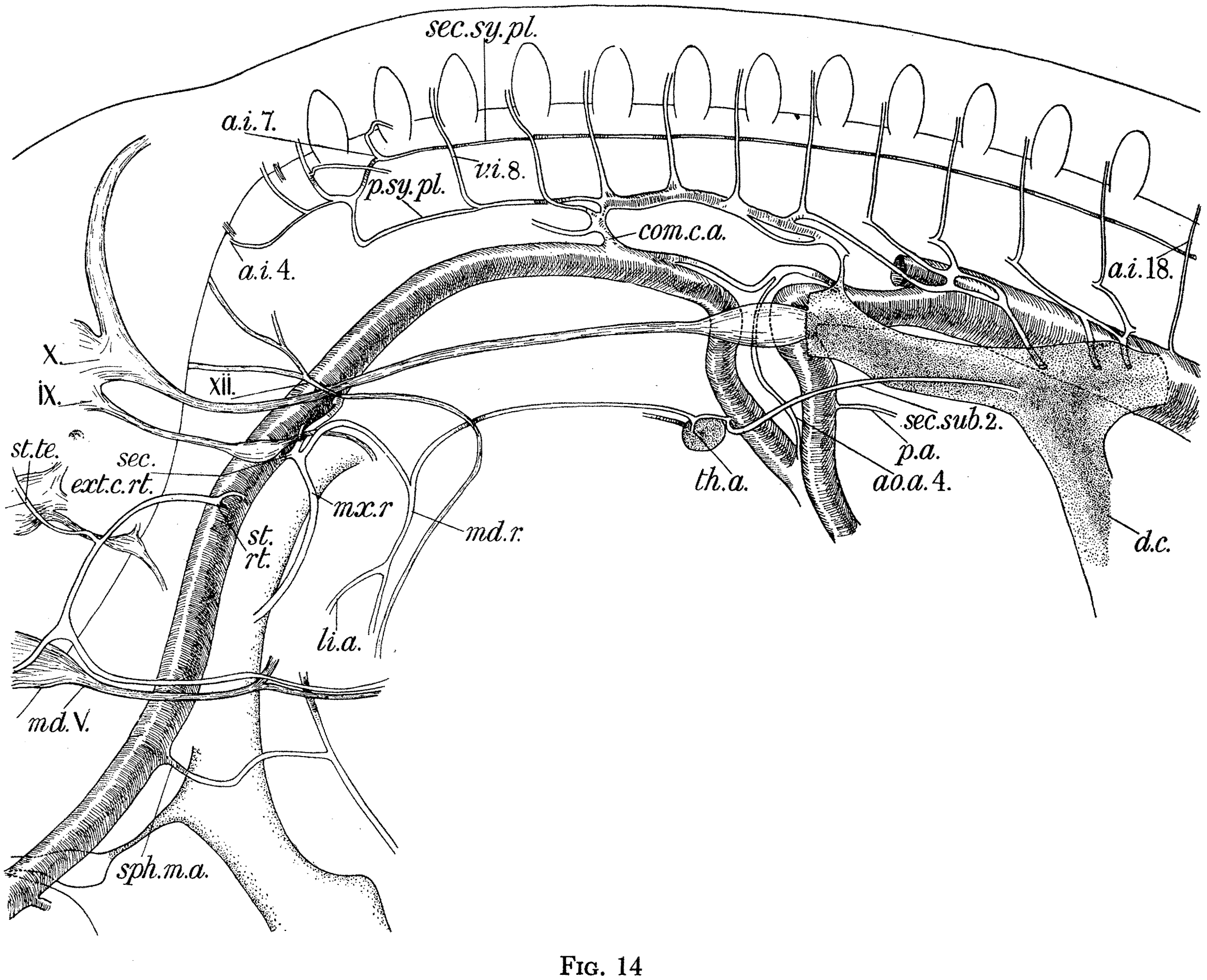
sec.sy.pl.
a.i.7.
v.i.8.
p.sy.pl.
com.c.a.
a.i.4.
a.i.18.
X.
IX.
XII.
sec.sub.2.
p.a.
st.te.
sec.
ext.c.rt.
th.a.
ao.a.4.
mx.r
st.
rt.
md.r.
d.c.
li.a.
md.V.
sph.m.a.

Fig. 14

PLATE 8

FIG. 15—Reconstruction of the head veins of an embryo of seven and a half days. The posterior cerebral vein has disappeared, and the primary Stammvene is arching upwards, with the upward growth of the hyoid visceral pouch. The root of the secondary Stammvene can be recognized, as in the six and a half day stage. Left side. × 20.

FIG. 17—Section through the developing temporal rete of the seven and a half day embryo of fig. 16, at the level indicated in that fig. The temporal rete still consists of a mass of capillaries surrounding the laterally directed branch of the trigeminal. × 44.

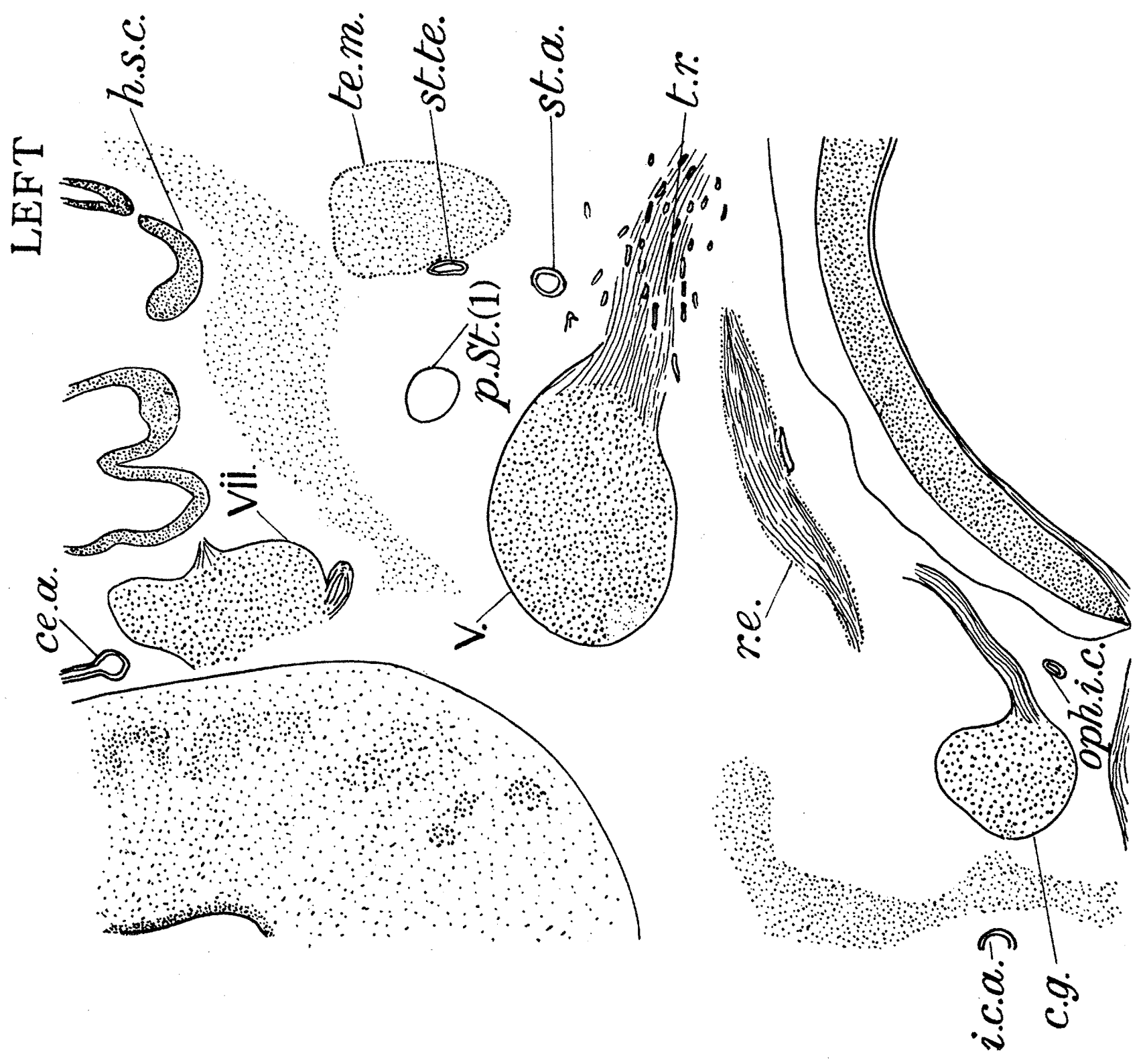
LEFT
h.s.c.
te.m.
st.te.
st.a.
t.r.
p.St.(1)
VII
ce.a.
V.
r.e.
oph.i.c.
c.g.
i.c.a.

FIG. 17

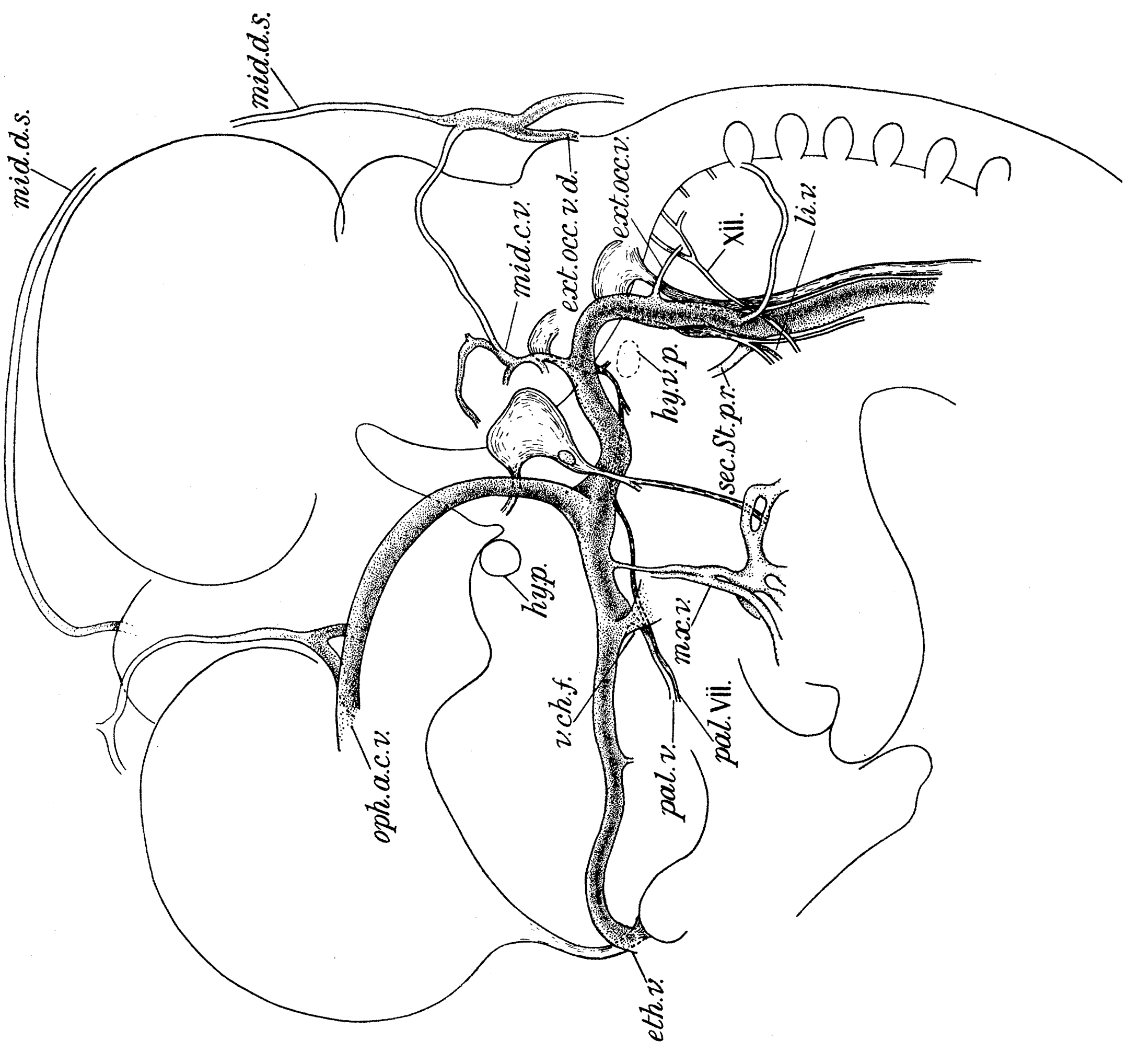
mid.d.s.
mid.d.s.
ext.occ.v.d.
ext.occ.v.
mid.c.v.
XII.
li.v.
hy.v.p.
sec.St.p.r.
hyp.
mx.v.
v.ch.f.
pal.VII.
pal.v.
oph.a.c.v.
eth.v.

FIG. 15

PLATE 9

FIG. 16—Reconstruction of the head arteries of an embryo of seven and a half days, not the same embryo as that of fig. 15. The left fourth aortic arch has disappeared, and the third and sixth aortic arches have taken up their adult positions. The carotid root of the vertebral artery is in the eighteenth interspace. Left side. × 17.

FIG. 23—Reconstruction of the head arteries of a chick at the hatching stage. The outline of the temporal rete is indicated, and all arteries within that area are seen through it, with the exception of the temporal branch of the stapedial, which lies lateral thereto. Left side. × 6.

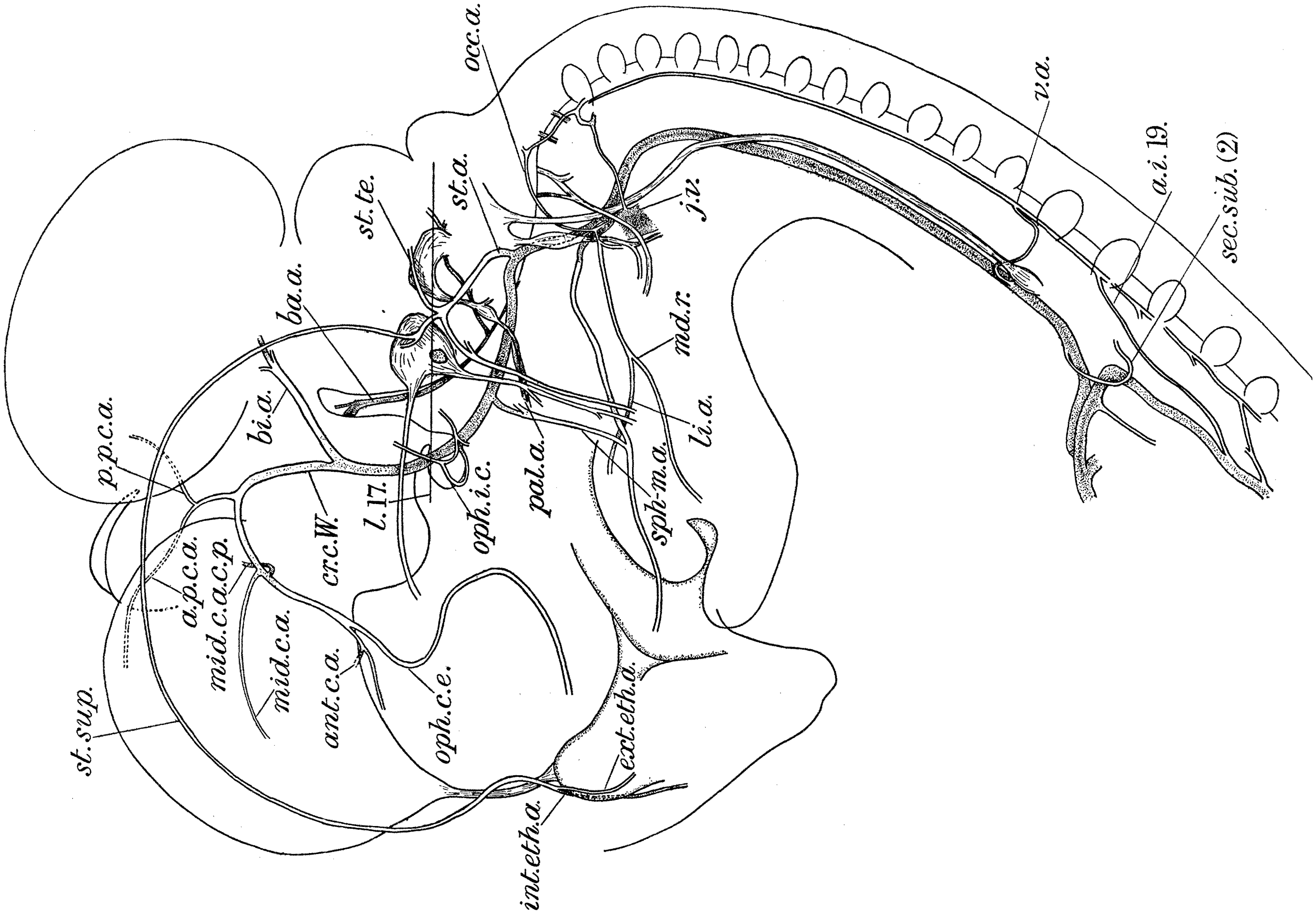
occ.a.
v.a.
a.i.19.
sec.sub.(2)
st.te.
st.a.
j.v.
ba.a.
md.r.
bi.a.
li.a.
p.p.c.a.
cr.c.W.
l.17.
oph.i.c.
pal.a.
sph-m.a.
a.p.c.a.
mid.c.a.c.p.
mid.c.a.
ant.c.a.
oph.c.e.
ext.eth.a.
st.sup.
int.eth.a.

Fig. 16

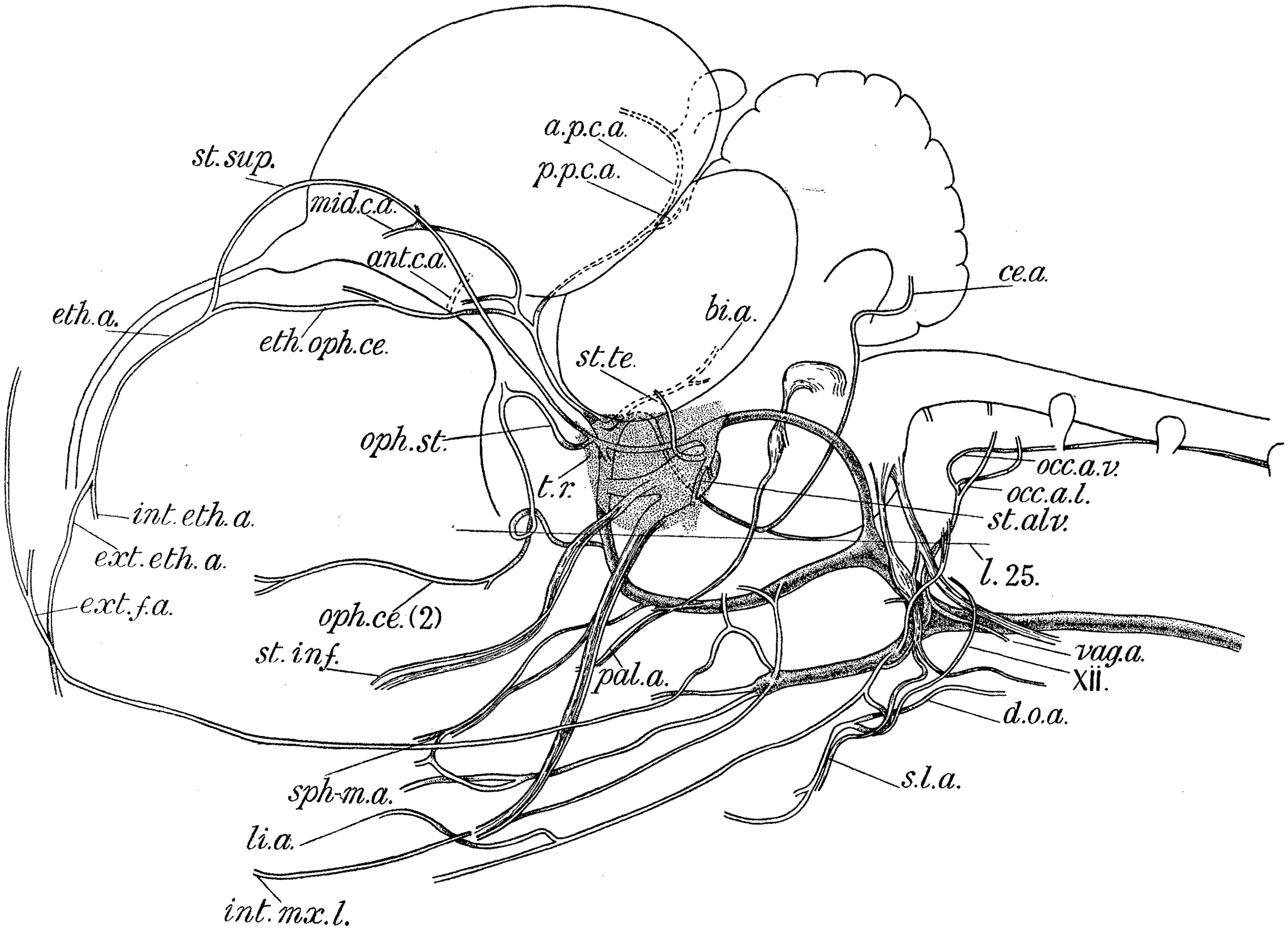
a.p.c.a.
p.p.c.a.
st.sup.
mid.c.a.
ant.c.a.
ce.a.
eth.a.
eth.oph.ce.
bi.a.
st.te.
oph.st.
occ.a.v.
t.r.
occ.a.l.
st.alv.
int.eth.a.
ext.eth.a.
l.25.
ext.f.a.
oph.ce.(2)
vag.a.
st.inf.
XII.
pal.a.
d.o.a.
s.l.a.
sph-m.a.
li.a.
int.mx.l.

Fig. 23

PLATE 10

FIG. 18—Reconstruction of the head veins of an embryo of eight and a half days. Both primary and secondary Stammvenen co-exist at this stage, and the external occipital vein is complete. Left side. × 17.

FIG. 24—Reconstruction of the head veins of a chick at the hatching stage, the embryo being the same as that of the preceding figure. In the temporal region, the temporal rete is most lateral, then comes the trigeminal, and medianally is seen the sinus of the sella turcica, which leads out caudally into the carotid vein, a collection of venules surrounding the internal carotid artery. Right side. × 6.

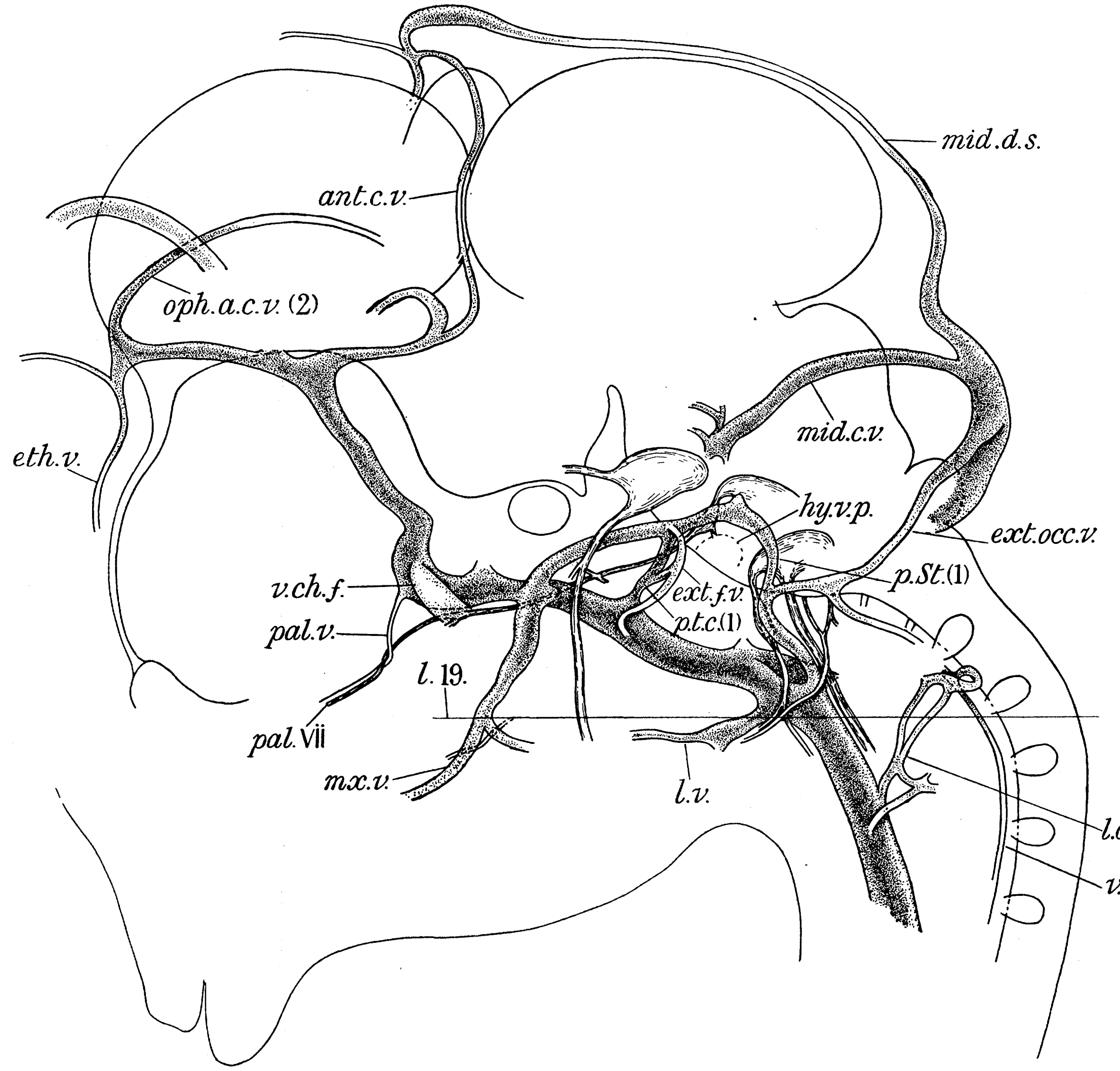
mid.d.s.
ant.c.v.
oph.a.c.v. (2)
mid.c.v.
eth.v.
hy.v.p.
ext.occ.v.
v.ch.f.
ext.f.v.
p.St.(1)
p.t.c.(1)
pal.v.
l. 19.
pal. VII
mx.v.
l.v.
l.occ.v.
v.v.

FIG. 18

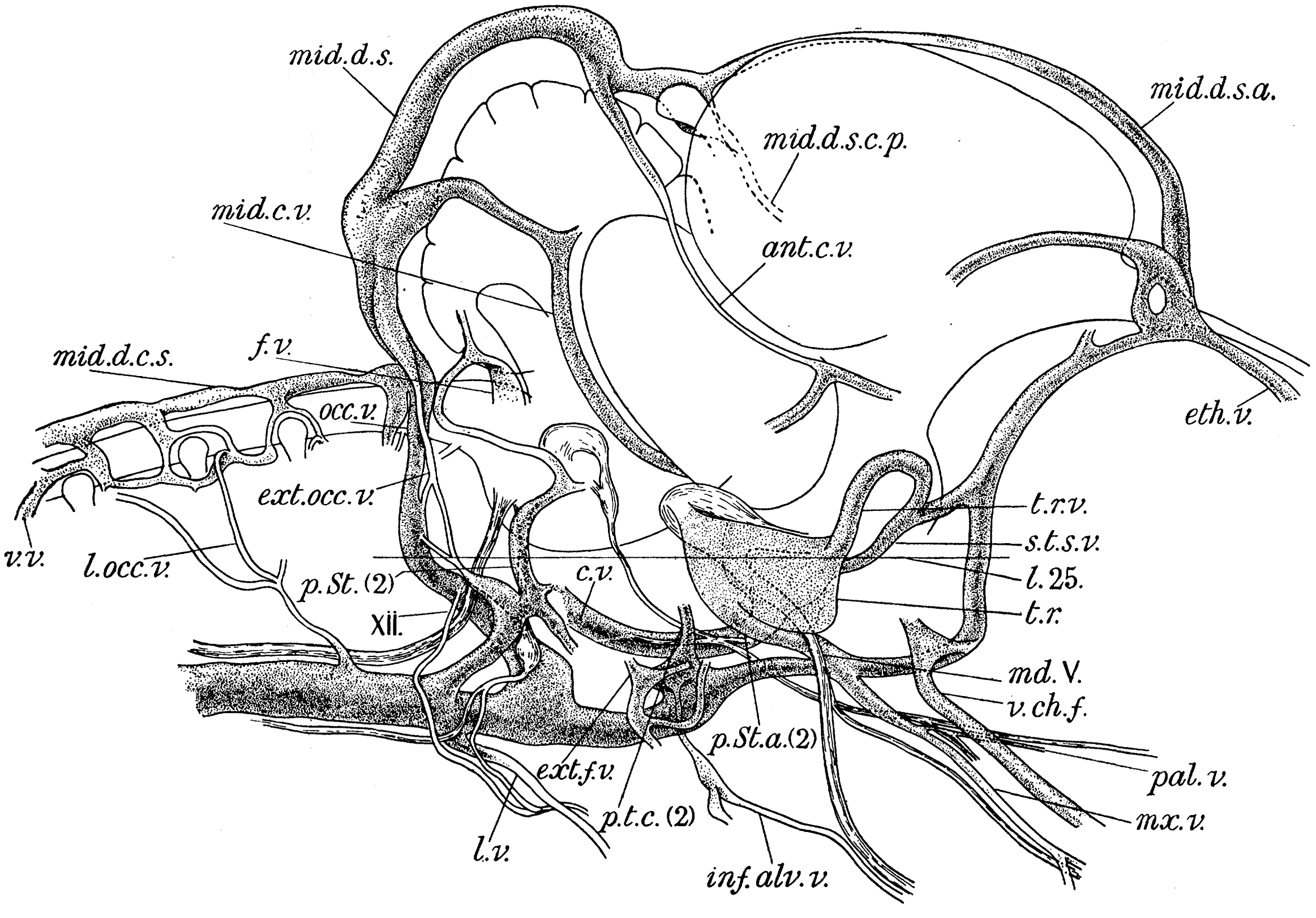
mid.d.s.
mid.d.s.a.
mid.d.s.c.p.
mid.c.v.
ant.c.v.
mid.d.c.s.
f.v.
eth.v.
occ.v.
ext.occ.v.
t.r.v.
s.t.s.v.
v.v.
l.occ.v.
l. 25.
p.St. (2)
c.v.
t.r.
XII.
md. V.
v. ch. f.
p.St.a.(2)
ext.f.v.
pal. v.
mx. v.
p.t.c. (2)
l.v.
inf. alv. v.

FIG. 24

PLATE 11

FIG. 19—Section through the eight and a half day embryo of fig. 18, at a level just above that of the cross-connection between the secondary Stammvenen. A median mass of venules represents the root of the median vessel which will spring from this point. The left side lies at a slightly higher level than the right. Thus on the right the external carotid is about to part from the main internal carotid stem, the which has already taken place on the left. The spheno-maxillary artery is becoming distinct from the maxillary vein, both of which are differentiated from the same capillary plexus. × 26.

FIG. 21—Reconstruction of the head veins of an embryo of twelve days. The anterior portion of the primary Stammvene has now disappeared, and the occipital veins are fully formed, communicating medially with the cross-anastomosis between the secondary Stammvenen. Right side. × 14.

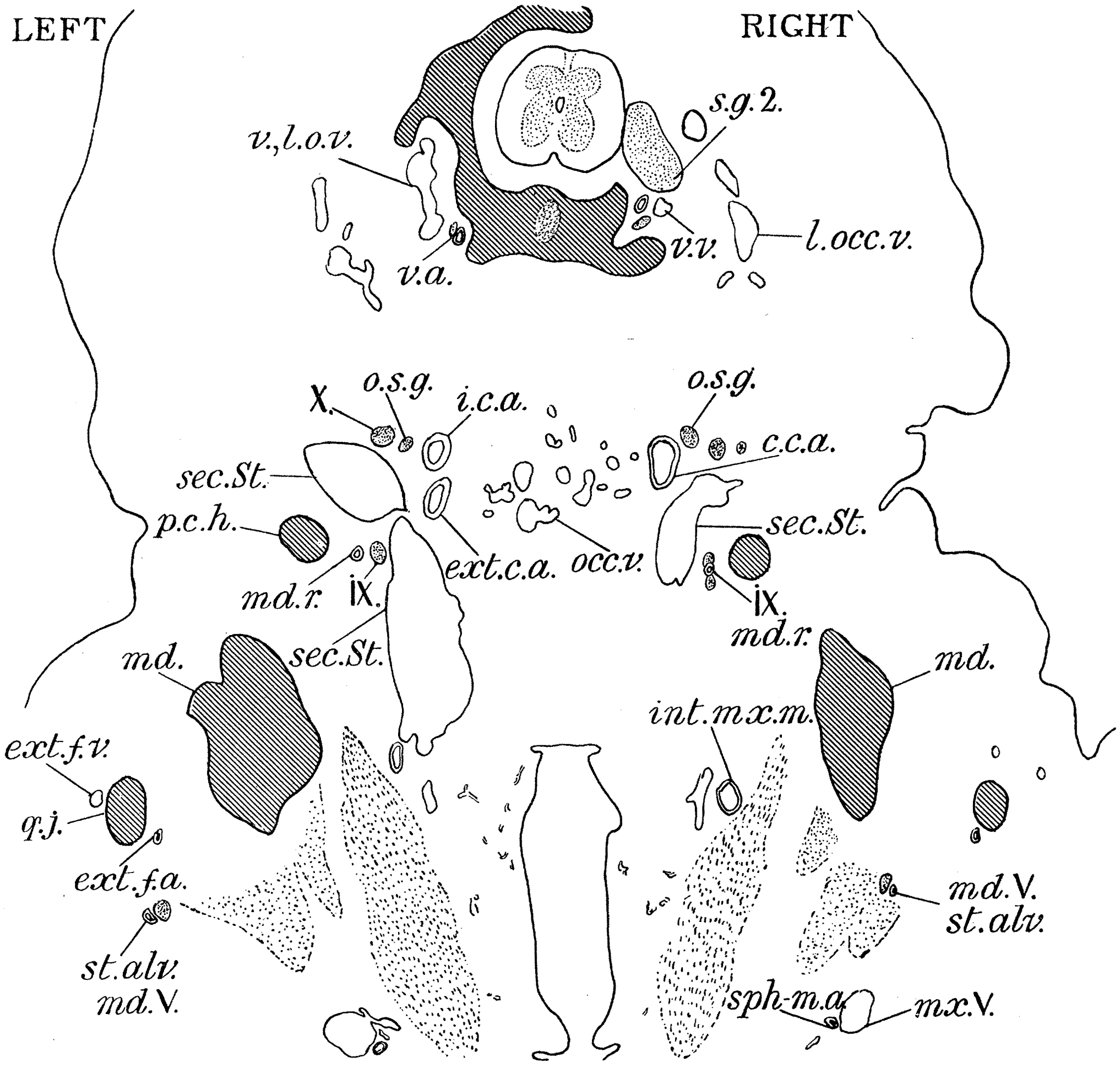
LEFT
RIGHT
v.,l.o.v.
s.g.2.
v.a.
v.v.
l.occ.v.
X.
o.s.g.
i.c.a.
o.s.g.
c.c.a.
sec.St.
sec.St.
p.c.h.
md.r.
IX.
ext.c.a.
occ.v.
IX.
md.r.
sec.St.
md.
md.
int.mx.m.
ext.f.v.
q.j.
ext.f.a.
md.V.
st.alv.
st.alv.
md.V.
sph-m.a.
mx.V.

FIG. 19

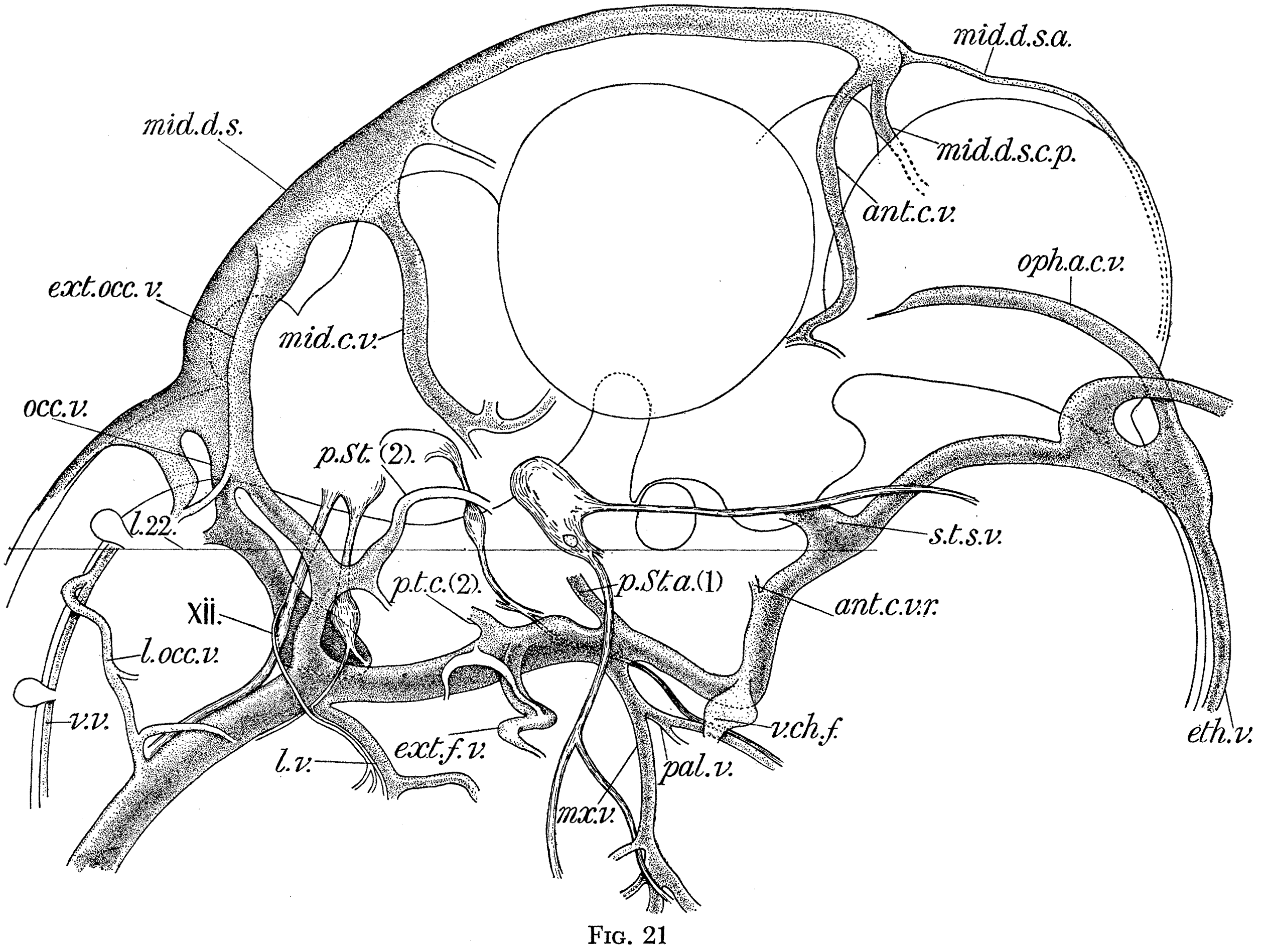
mid.d.s.a.
mid.d.s.
mid.d.s.c.p.
ant.c.v.
oph.a.c.v.
ext.occ.v.
mid.c.v.
occ.v.
p.St.(2).
l.22.
s.t.s.v.
p.t.c.(2).
p.St.a.(1)
XII.
ant.c.v.r.
l.occ.v.
v.v.
ext.f.v.
v.ch.f.
l.v.
pal.v.
mx.v.
eth.v.

FIG. 21

PLATE 12

FIG. 20—Reconstruction of the head arteries of an embryo of nine days. Most vessels have by now acquired definitive form, the which is not yet true of the veins. In this embryo, the carotid root of the vertebral artery is in the seventeenth interspace. Right side. × 17.

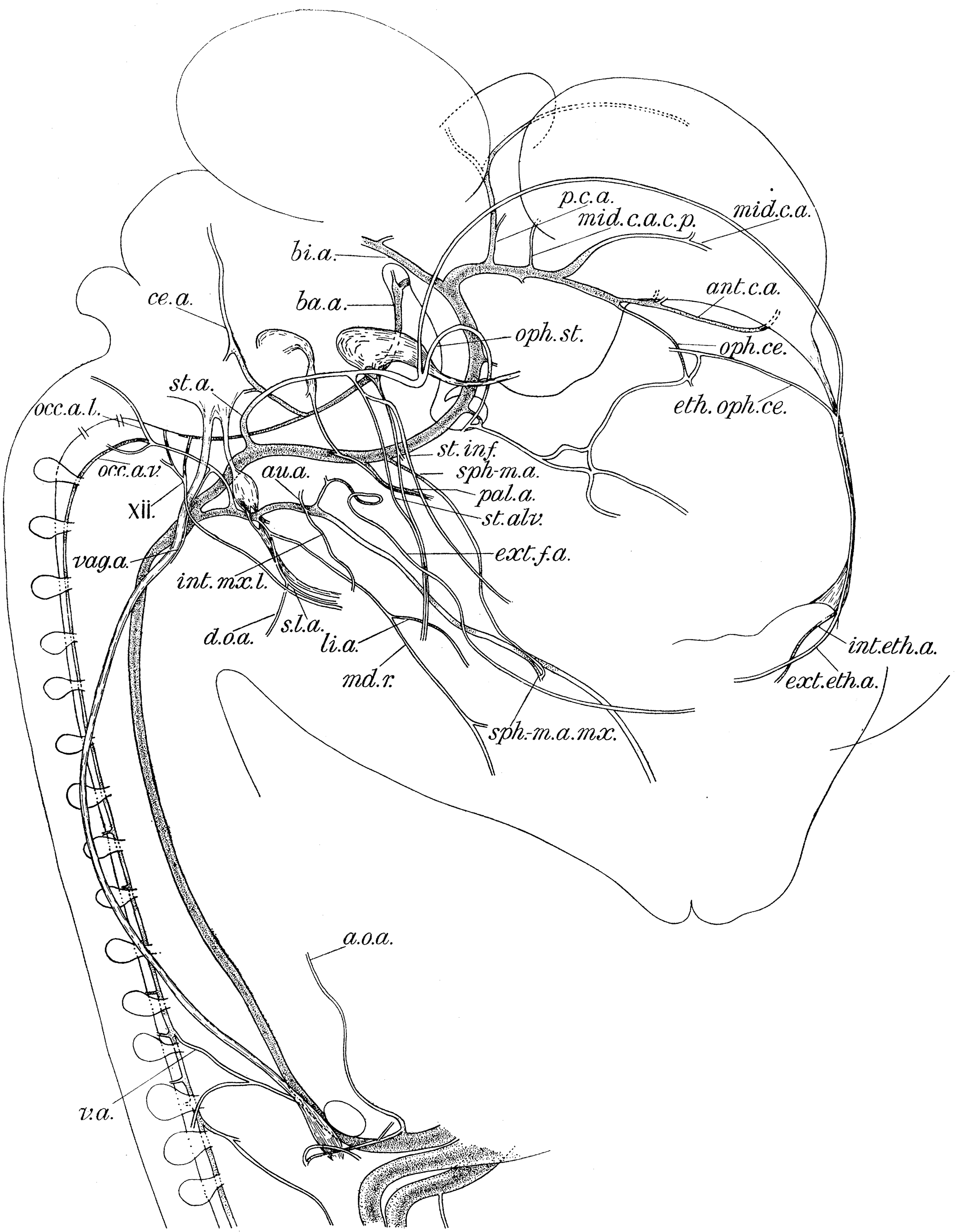
p.c.a.
mid.c.a.c.p.
mid.c.a.
bi.a.
ba.a.
ce.a.
ant.c.a.
oph.st.
oph.ce.
eth. oph.ce.
st.a.
occ.a.l.
occ.a.v.
st. inf.
sph-m.a.
pal.a.
XII.
au.a.
st.alv.
vag.a.
int. mx.l.
ext.f.a.
d.o.a.
s.l.a.
li.a.
md.r.
int.eth.a.
ext.eth.a.
sph-m.a.mx.
a.o.a.
v.a.

Fig. 20

PLATE 13

FIG. 22—Section through the twelve day embryo of fig. 21, at the level indicated in that figure. The medial connection between the cross-anastomosis between the secondary Stammvenen and the occipital veins has the form of one large vessel on each, together with several venules. The right side lies at a higher level than the left. The primary Stammvenen has left the external occipital vein on the right side, but not on the left ; on the left the stapedial artery is only just separating from the internal carotid. The left side lies below the ophthalmic of the internal carotid. Venules have aggregated within the sella turcica, but as yet none lead out along the internal carotid, or into the orbit with the ophthalmic artery. × 17.

FIG. 28—Reconstruction of the secondary external carotid of the nine day embryo of fig. 20. Left side. Here, the maxillary ramus is lateral to the glossopharyngeal. × 55.

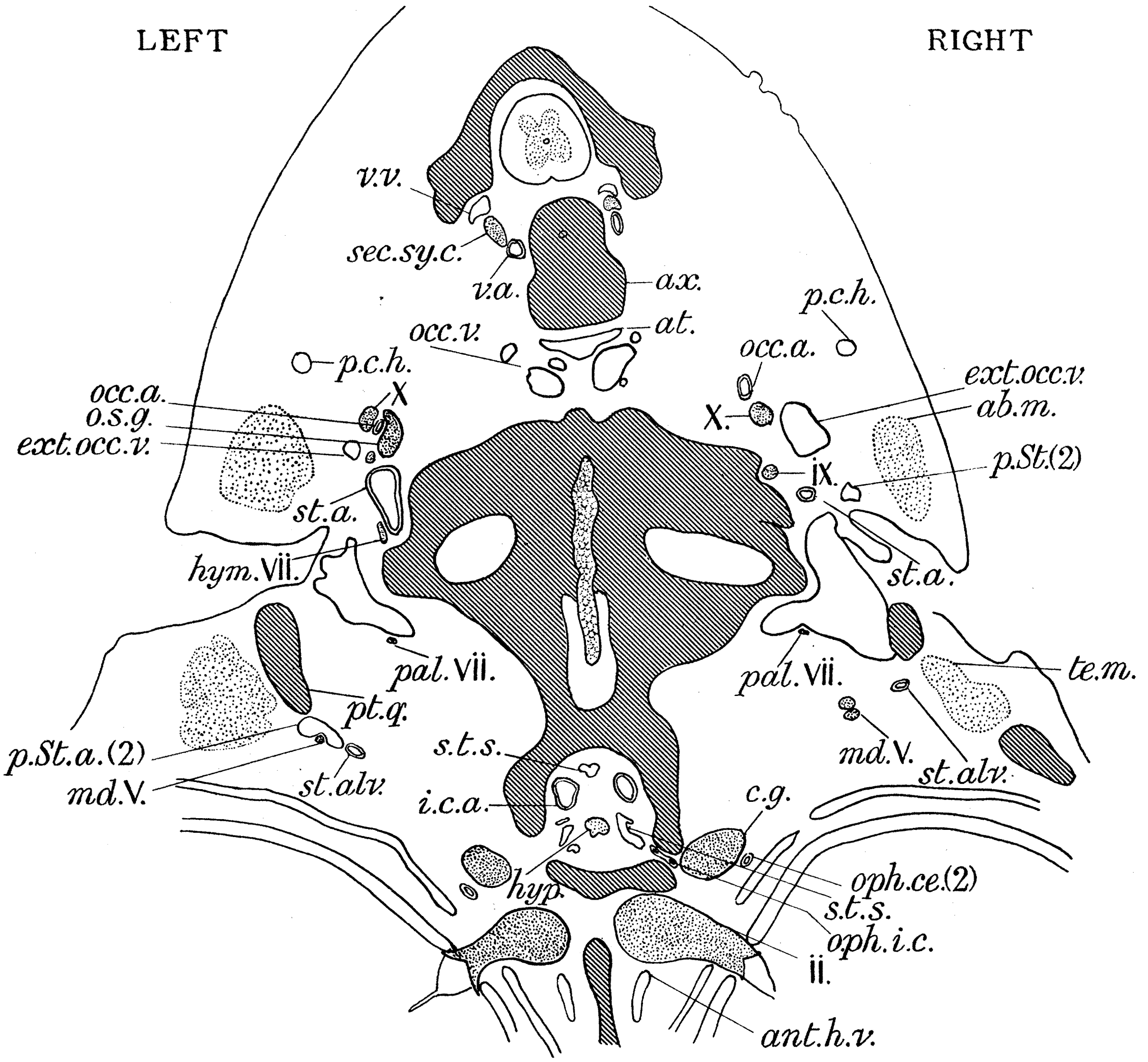
LEFT
RIGHT
v.v.
sec.sy.c.
v.a.
ax.
at.
p.c.h.
occ.v.
p.c.h.
occ.a.
ext.occ.v.
occ.a.
X
o.s.g.
ext.occ.v.
X.
ab.m.
ix.
p.St.(2)
st.a.
hym.VII.
st.a.
pal.VII.
pal.VII.
te.m.
pt.q.
p.St.a.(2)
md.V.
s.t.s.
st.alv.
md.V.
st.alv.
i.c.a.
c.g.
oph.ce.(2)
hyp.
s.t.s.
oph.i.c.
ii.
ant.h.v.

Fig. 22

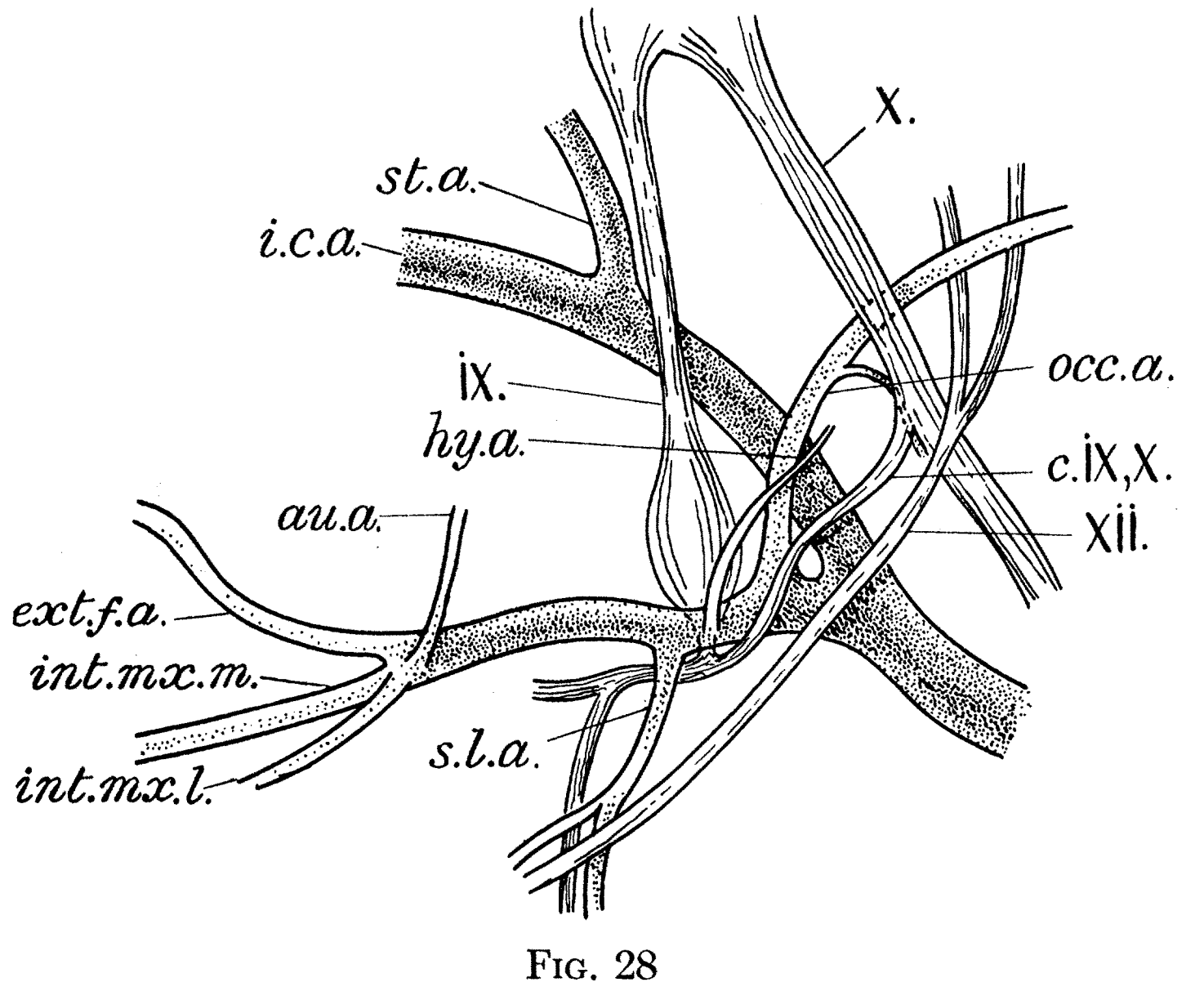
X.
st.a.
i.c.a.
IX.
occ.a.
hy.a.
c.IX,X.
XII.
au.a.
ext.f.a.
int.mx.m.
int.mx.l.
s.l.a.

Fig. 28

PLATE 14

FIG. 25—Section through the chick at the hatching stage of figs. 23 and 24, at a level below that of the base of the brain, as shown in these figures. The right side lies at a higher level than the left, and passes through the temporal rete, and the laterally directed branch of the trigeminal. The median section of the occipital veins below the level of the brain now have the form of a single large vessel on each side. The venules of the sella turcica sinus now occupy the whole of that space not filled by other structures. × 14

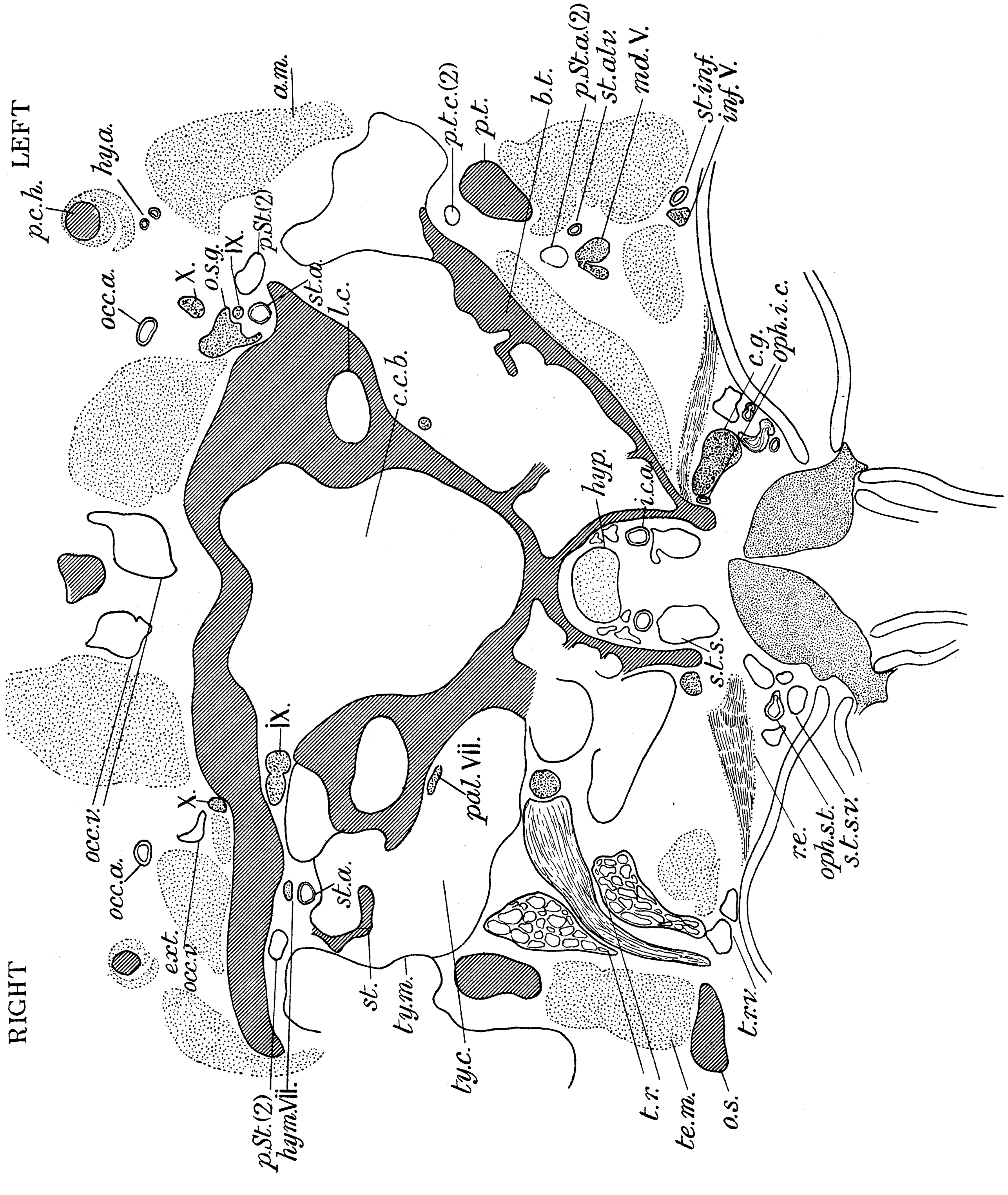
LEFT
RIGHT
p.c.h.
hy.a.
a.m.
occ.a.
X.
o.s.g.
IX.
p.St.(2)
st.a.
l.c.
p.t.c.(2)
p.t.
b.t.
p.St.a.(2)
st.alv.
md.V.
st.inf.
inf.V.
c.c.b.
c.g.
oph.i.c.
hyp.
i.c.a.
s.t.s.
occ.v.
IX.
pal.VII.
X.
occ.a.
ext.
occ.v.
st.a.
st.
ty.m.
ty.c.
p.St.(2)
hym.VII.
t.r.
te.m.
o.s.
t.r.v.
r.e.
oph.s.t.
s.t.s.v.

Fig. 25

Plate 15

Fig. 26—Reconstruction of the secondary external carotid of the six and a half day embryo of figs. 11 and 12. The maxillary and mandibular rami are still in a plexiform condition. Left side. × 70.

Fig. 27—Reconstruction of the secondary external carotid of the seven and a half day embryo of figs. 16 and 17. In this embryo the maxillary and mandibular rami unite behind the glossopharyngeal. Left side. × 88.

Fig. 29—Reconstruction of the secondary external carotid of the nine day embryo of fig. 20. Right side. Here the glossopharyngeal bifurcates round the maxillary ramus. × 55.

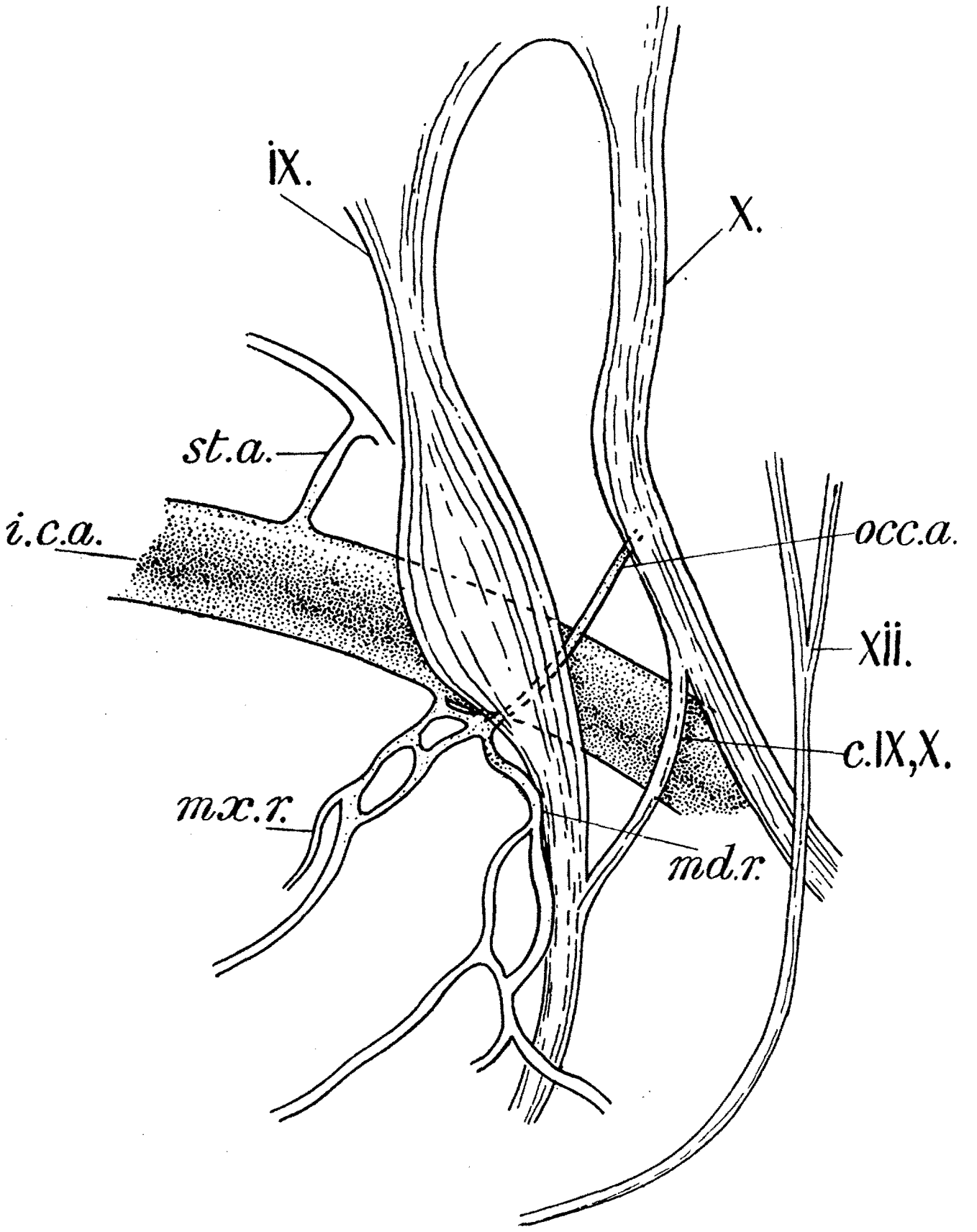

Fig. 26

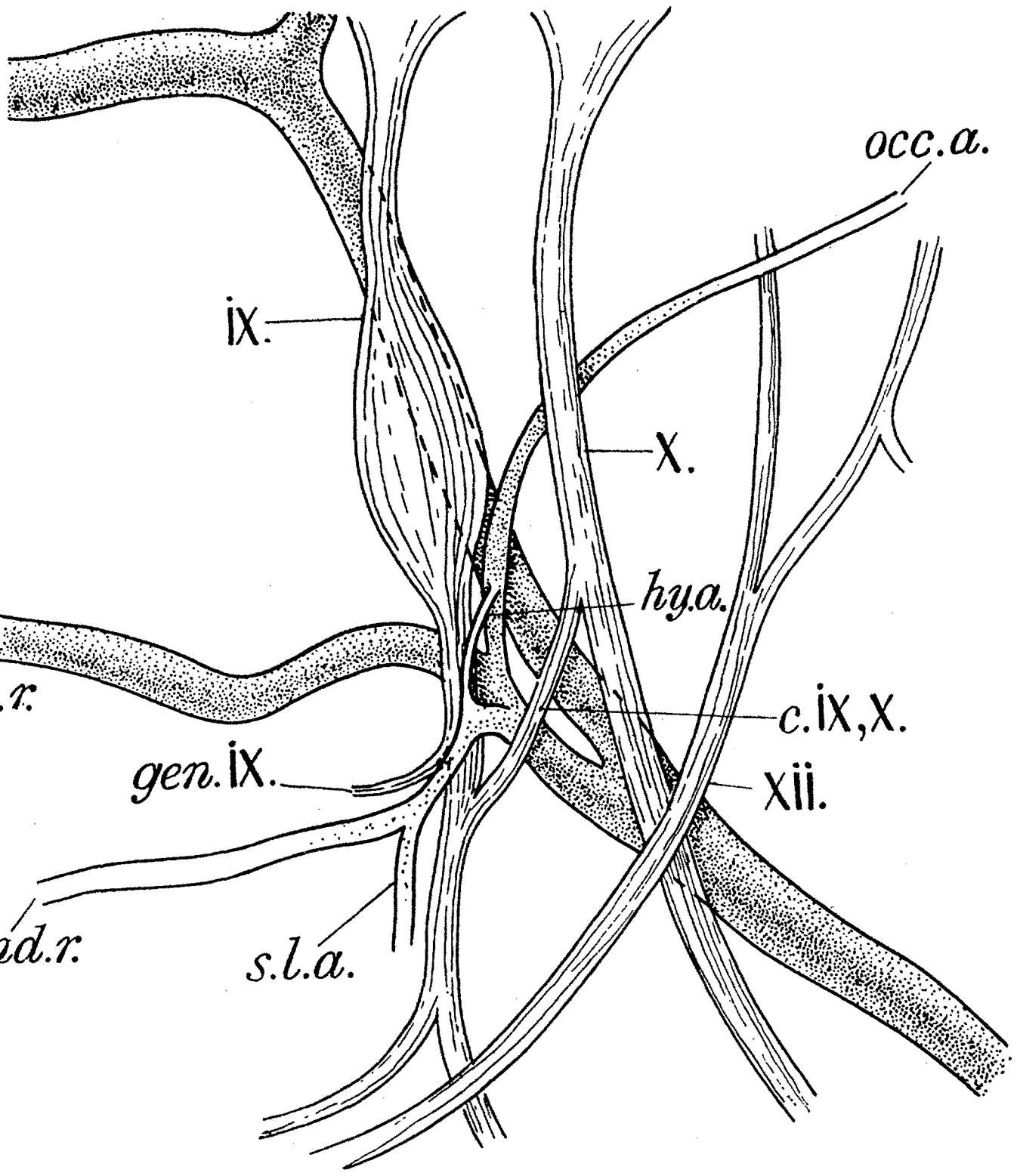

Fig. 27

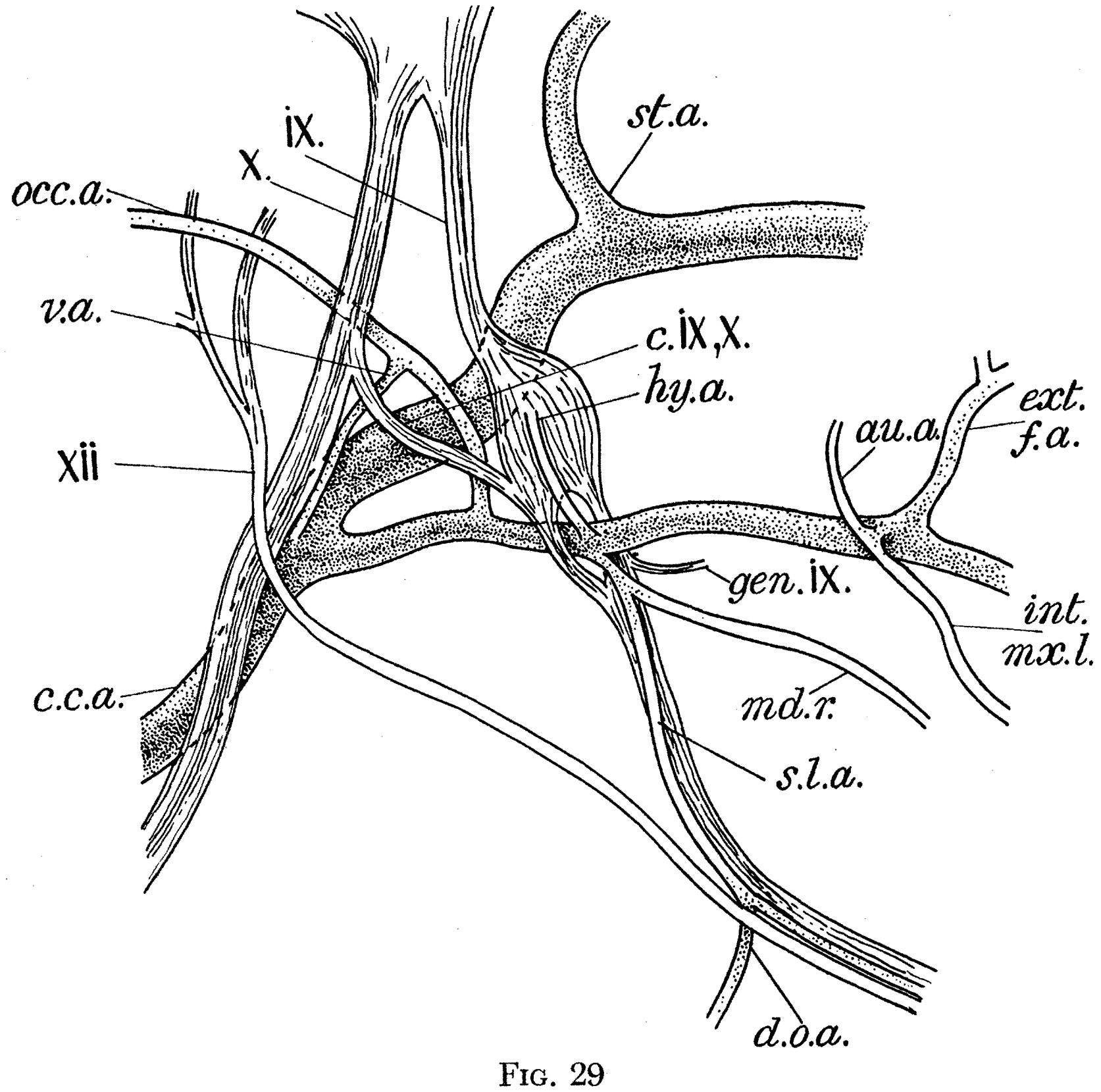

Fig. 29

PLATE 16

FIG. 30—Reconstruction of the secondary external carotid of the twelve day embryo of figs. 21 and 22. Left side. × 44.

FIG. 31—Reconstruction of the secondary external carotid of the chick at the hatching stage of figs. 23 to 25. Left side. × 20.

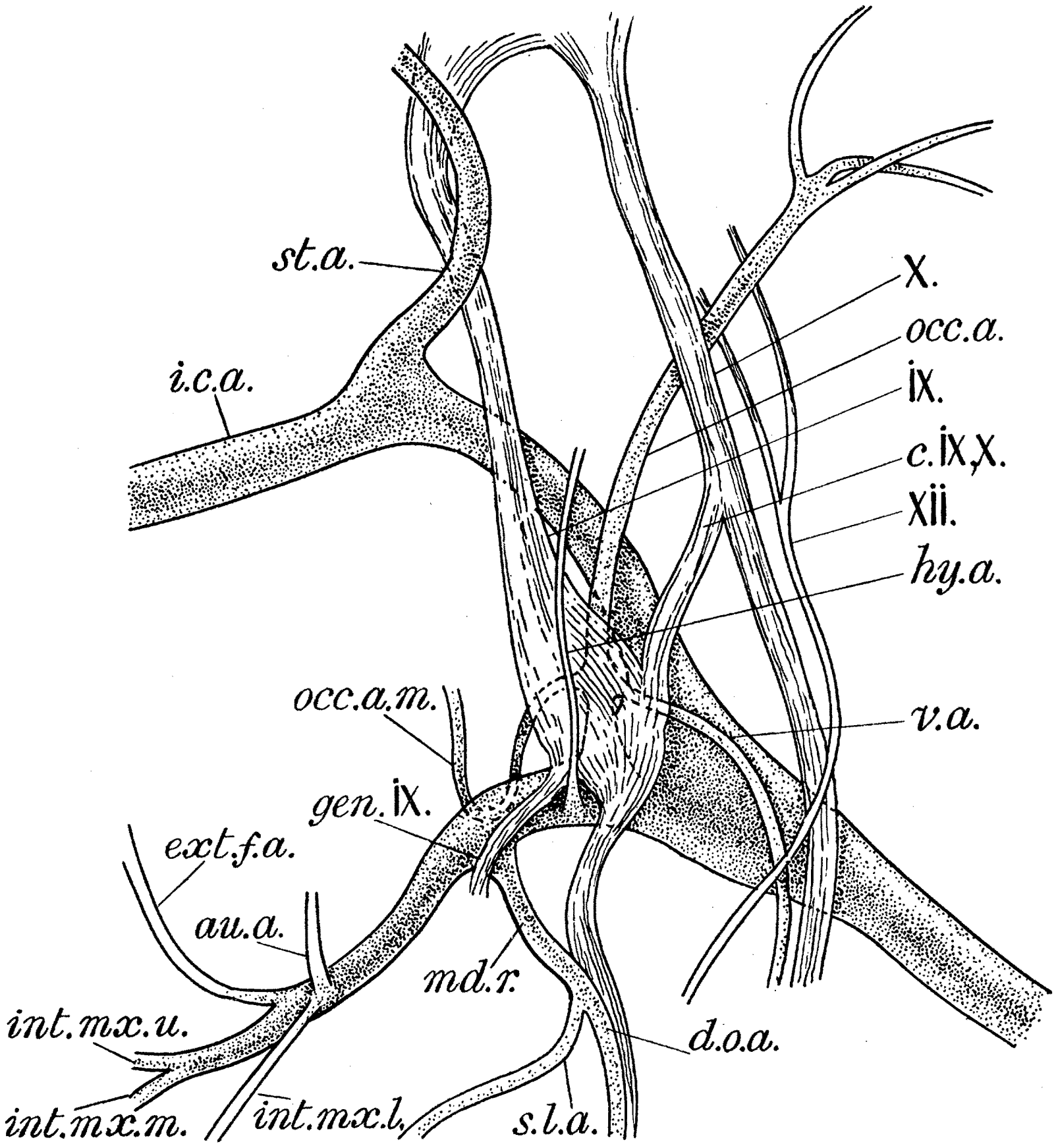
st.a.
i.c.a.
X.
occ.a.
IX.
c.IX,X.
XII.
hy.a.
occ.a.m.
v.a.
gen.IX.
ext.f.a.
au.a.
md.r.
int.mx.u.
d.o.a.
int.mx.m.
int.mx.l.
s.l.a.

FIG. 30

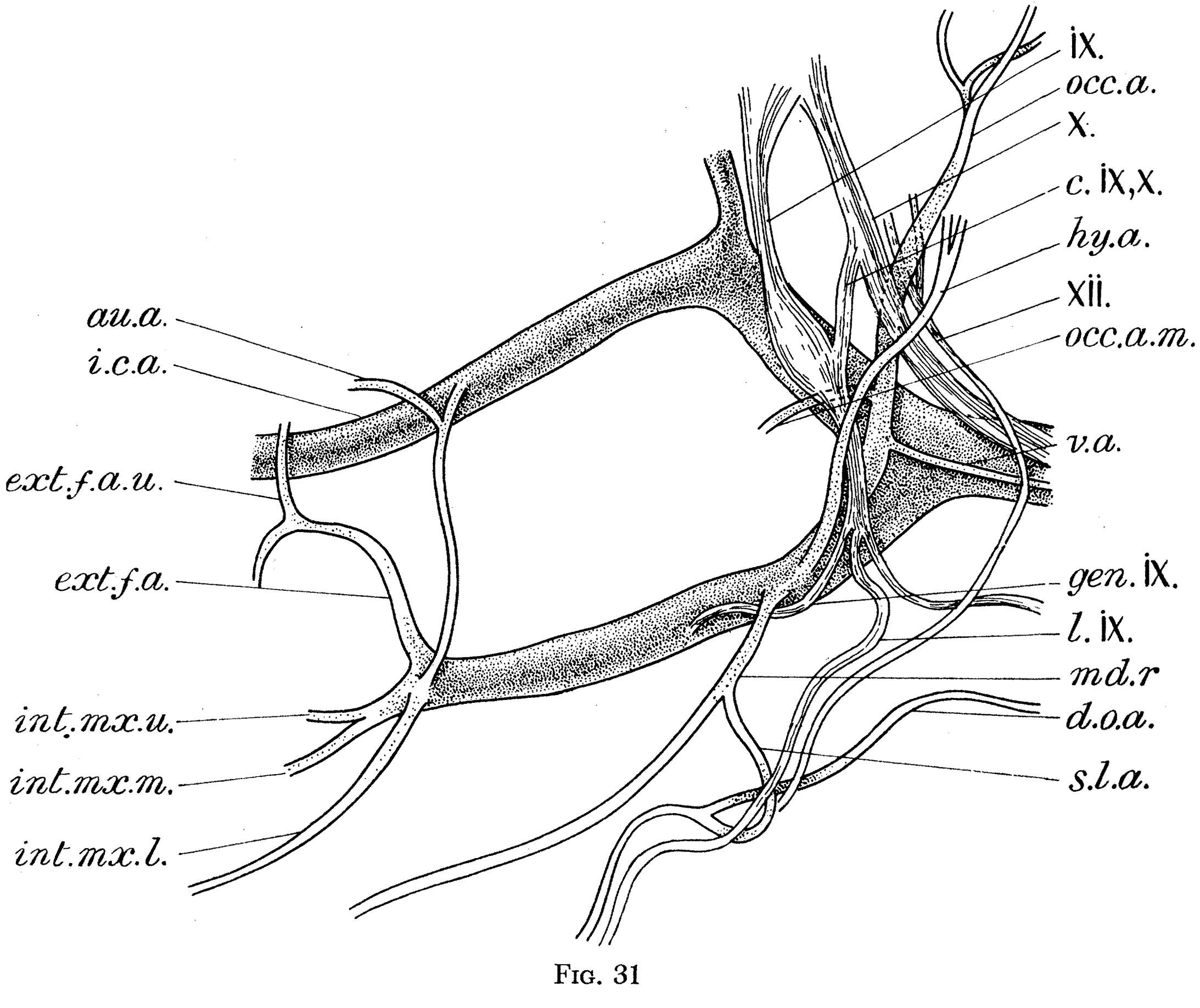
IX.
occ.a.
X.
c.IX,X.
hy.a.
au.a.
XII.
i.c.a.
occ.a.m.
v.a.
ext.f.a.u.
ext.f.a.
gen.IX.
l.IX.
md.r
int.mx.u.
d.o.a.
int.mx.m.
s.l.a.
int.mx.l.

FIG. 31

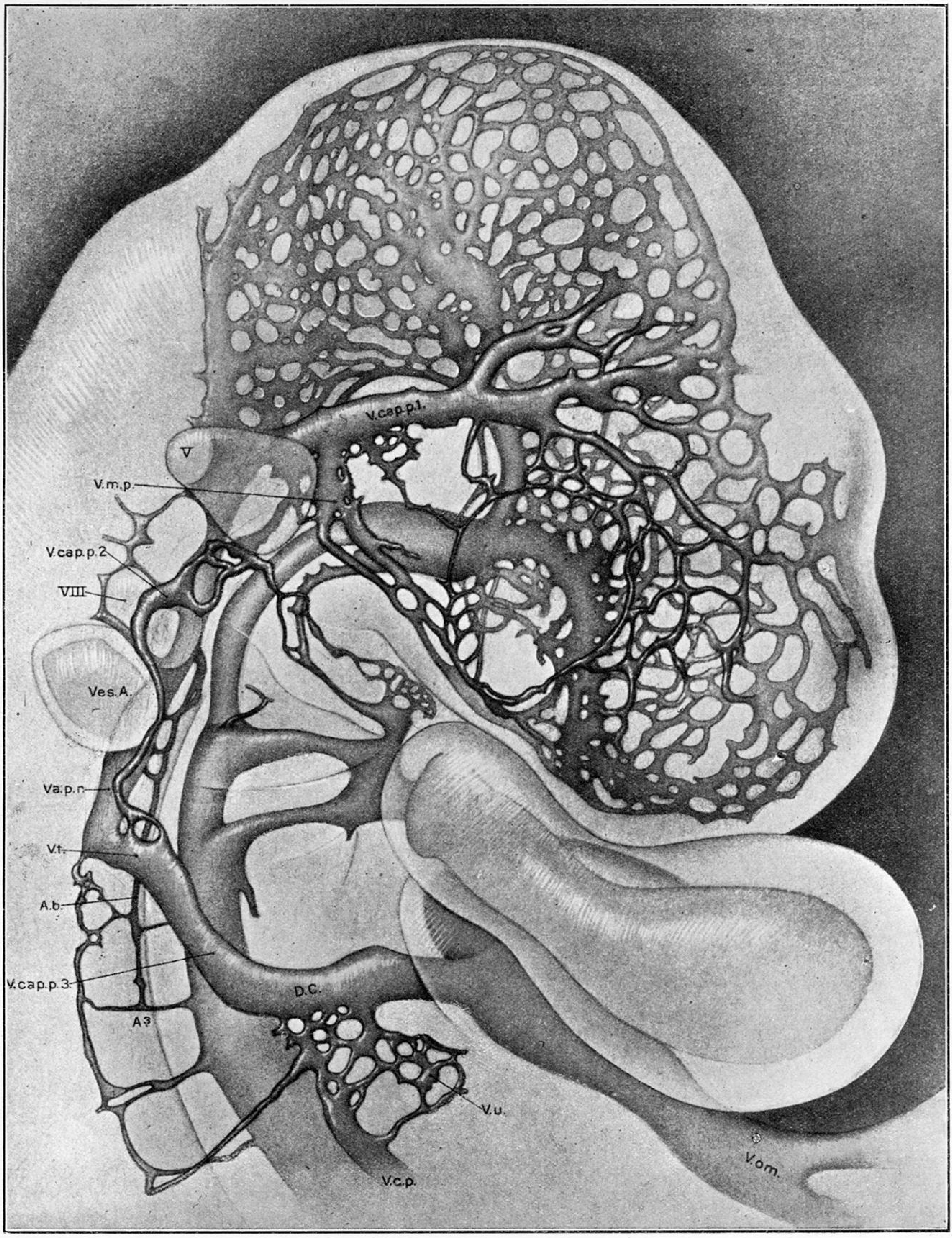

FIG. 1

PLATE 1

FIG. 1—Reproduction of Miss SABIN's Plate 6, of a chick embryo of twenty-nine somites. Right side. The legend thereto is as follows :—

The vena capitis prima arises in three segments :—

1. (*v.cap.p.*1.) a true primitive cerebral vein, draining the fore-brain, and will soon drain the mid-brain.
2. (*v.cap.p.*2) an anastomosis between maxillary, mandibular, the other visceral arches, and the anterior cardinal vein, draining the brain and the visceral arches.
3. (*v.cap.p.*3) the anterior cardinal vein, draining the brain and the visceral arches.

A.b., artery on the rhombencephalon, bilateral at this stage, and part of a plexus which will give rise to the basilar artery.
*A.*3., artery to the medulla in the third interspace.
d.C., ductus Cuvieri.
v.c.p., posterior cardinal vein.
v.m.p., vena maxillaris primitiva.
v.om., omphalo-mesenteric vein.
v.t., transverse vein of the first interspace.
v.u., plexus in which umbilical vein will arise.
va.p.r., vasa primitiva rhombencephali.
ves.a., auditory vesicle.